

Chiara Cristinzio^{1,2}, David Sander^{2,3}, Patrik Vuilleumier^{1,2}

¹ Laboratory for Behavioural Neurology and Imaging of Cognition, Department of Neuroscience and Clinic of Neurology, University of Geneva

² Swiss Center for Affective Sciences, University of Geneva

³ Department of Psychology, University of Geneva

Abstract

The amygdala is often damaged in patients with temporal lobe epilepsy, either because of the primary epileptogenic disease (e.g. sclerosis or encephalitis) or because of secondary effects of surgical interventions (e.g. lobectomy). In humans, the amygdala has been associated with a range of important emotional and social functions, in particular with deficits in emotion recognition from faces. Here we review data from recent neuropsychological research illustrating the amygdala role in processing facial expressions. We describe behavioural findings subsequent to focal lesions and possible factors that may influence the nature and severity of deficits in patients. Both bilateral and unilateral amygdala damage can impair the recognition of facial emotions, especially fear, but such deficits are not always present and not always specific. Moreover, not all components of emotion or fear processing are impaired after amygdala damage. Dissociations have been reported between deficits in the recognition of emotions from the face of other people, and intact ability in the production of emotions in one's own facial expression after amygdala damage. In addition, residual implicit effects during processing of emotional stimuli can also be preserved in some patients with amygdala lesion. A great variability in the effects of amygdala damage on emotion processing has been observed and suggests that other important factors have to be considered: these include the aetiology of damage, and the age of disease onset. We propose that a more detailed assessment of emotional processing in patients with temporal lobe epilepsy may provide not only novel information about the role of amygdala in humans, but also useful clinical measures to assess temporal lobe functions in epilepsy patients.

Epileptologie 2007; 24: 130 – 138

Key words: Amygdala, emotion, facial expression, mesial temporal lobe, development

* Acknowledgements

This work was supported by a grant of the SNF (No 105311-108187) to David Sander and Patrik Vuilleumier, and by the Swiss National Center for Affective Sciences. We thank Karim N'Diaye, Gilles Pourtois, and Margitta Seeck for collaboration and support during this research.

Reconnaissance d'expressions faciales émotionnelles et pathologie de l'amygdale

L'amygdale de patients atteints d'une épilepsie du lobe temporal est souvent affectée, soit en raison de leur maladie épileptogénique primaire (p.ex. sclérose ou encéphalite), soit en raison des effets secondaires d'interventions chirurgicales (p.ex. lobectomie). L'amygdale a été associée à une gamme de fonctions émotionnelles et sociales importantes dans l'organisme humain, en particulier à certains déficits dans la faculté de décrypter des émotions sur le visage. Nous passons ici en revue les résultats des récents travaux de la neuropsychologie illustrant le rôle de l'amygdale dans le traitement cognitif des expressions faciales. Nous décrivons des caractéristiques comportementales typiques des lésions focales et des facteurs susceptibles d'influencer la nature et la sévérité des déficits de patients. Une lésion de l'amygdale, qu'elle soit unilatérale ou bilatérale, peut entraver la perception d'émotions faciales, surtout de la peur, mais de tels déficits ne sont pas automatiques, ni toujours spécifiques. De plus, toutes les opérations de traitement d'émotions ou de la peur ne sont pas concernées par une lésion de l'amygdale. Ainsi, on a vu des sujets qui, suite à une lésion de l'amygdale, étaient incapables de lire les émotions sur le visage d'autrui, tandis que leur faculté d'exprimer des émotions à travers leur propre expression faciale restait parfaitement intacte. Certains effets résiduels implicites du processus de stimuli émotionnels peuvent aussi être préservés dans des patients avec une lésion de l'amygdale. De très grandes différences ont été notées dans les effets d'une lésion de l'amygdale sur le traitement des émotions, suggérant que d'autres facteurs importants doivent être pris en compte tels que l'étiologie de la lésion et l'âge auquel la maladie s'est déclarée. Nous pensons qu'une étude plus approfondie de la capacité de traitement de données émotionnelles par les patients atteints d'une épilepsie du lobe temporal pourra non seulement nous éclairer davantage sur le rôle de l'amygdale chez l'homme, mais aussi nous livrer des paramètres cliniques utiles pour mesurer les fonctions du lobe temporal chez les patients atteints d'épilepsie.

Mots clés: Epilepsie du lobe temporal, amygdala, émotion, cognition

Das Erkennen emotionaler Gesichtsausdrücke bei Schädigungen der Amygdala

Bei Patienten mit mesialer Temporallappenepilepsie ist die Amygdala häufig geschädigt aufgrund der primären epileptogenen Läsion oder durch eine Resektion dieser Struktur infolge einer epilepsiechirurgischen Behandlung. Der Amygdala kommt beim Menschen eine erhebliche Bedeutung bei der Verarbeitung emotionaler und sozialer Reize zu. In diesem Artikel wird der aktuelle Forschungsstand zur Rolle der Amygdala bei der Verarbeitung emotionaler Gesichtsausdrücke vorgestellt. Wir beschreiben Verhaltensdaten in Abhängigkeit vom Vorliegen einer amygdalären Läsion und analysieren die Auswirkungen weiterer Faktoren auf die Qualität und Quantität von Defiziten in der Verarbeitung von Gesichtsausdrücken. Sowohl unilaterale als bilaterale Amygdalaläsionen können das Erkennen emotionaler und insbesondere angsterfüllter Gesichtsausdrücke beeinträchtigen. Diese Defizite sind jedoch weder obligat noch spezifisch und nicht alle Aspekte der Verarbeitung von emotionalen Gesichtsausdrücken sind durch Amygdalaläsionen betroffen. So gibt es Dissoziationen zwischen der Fähigkeit zur Wahrnehmung und dem Vermögen, den eigenen Gesichtsausdruck zu modulieren. Darüber hinaus sind oft noch Residuen impliziten Erkennens gegeben. Die grosse interindividuelle Variabilität von Defiziten nach Amygdalaläsionen legt nahe, dass ätiologische Faktoren und das Alter zum Zeitpunkt der Läsion von erheblicher Bedeutung sind. Wir vermuten, dass eine dezidierte Diagnostik des Erkennens emotionaler Gesichtsausdrücke bei Patienten mit Temporallappenepilepsie nicht nur neue Information über die Rolle der Amygdala in der menschlichen Informationsverarbeitung zu liefern vermag, sondern dieser Bereich auch zu den klinisch bedeutsamen Domänen gehört, der auch für die klinische Diagnostik der Temporallappenepilepsie von Nutzen sein kann.

Schlüsselwörter: Amygdala, Emotion, Gesichtsausdruck, mesialer Temporallappen, Entwicklung

Introduction

Faces are special social stimuli that humans learn to

recognize since the early period of life. The expression of faces can inform us about the emotions and intentions of other persons, and influence consequently our behaviour and own emotions. Selective deficits in the ability to recognize emotional expressions may occur following neurological diseases, indicating that the human brain is equipped with specialized circuits for discriminating facial emotions. In particular, a crucial involvement of the amygdala in emotional face processing has been demonstrated by a large number of studies in both brain-damaged patients and normal subjects. However, impairments in emotion recognition from faces after amygdala damage may be highly variable across different patients and across different types of emotion. Therefore the exact role of the human amygdala in emotion and face processing still remains unresolved.

Factors that may account for this variability include the site, extent, and nature of pathology (Figure 1), the bilateral or unilateral distribution of lesions, hemispheric

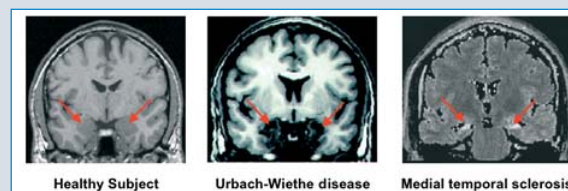

Figure 1. Illustration of different causes of amygdala lesions. Coronal MRI slices from (A) a healthy subject; (B) a patient with Urbach-Wiethe disease (from [2]); and a patient with medial temporal sclerosis.

side, as well as the aetiology, onset and/or duration of disease, plus the cognitive demands of different tests. Table 1 summarizes the more frequent causes of amygdala lesion. Among these causes, temporal lobe epilepsy (TLE) is a frequent pathology in clinical practice, in which amygdala and hippocampus are often selectively damaged. Such damage may be primary (due to the epileptogenic disease itself) or secondary to surgical treatment (lobectomy or amygdalo-hippocampectomy). We believe that a better understanding of emotional deficits associated with amygdala pathology is important to improve the neuropsychological assessment of patients with medial temporal lobe disease, in

Table 1

Most common causes of amygdala lesion.

Lesion	Aetiology		Onset	
Bilateral	Congenital (e.g. Urbach-Wiethe disease)		early	
	Acquired (e.g. encephalitis)		late	
Unilateral	Temporal lobe epilepsy	before neurosurgery	early	
		after neurosurgery	mesial temporal sclerosis	late
			other	late
		lobectomy including amygdala	late	

addition to yielding valuable new insights into the cerebral mechanisms of social and affective processes.

Here we review recent studies that investigated emotional face recognition problems in amygdala-damaged patients and describe different factors that may influence the clinical severity of these problems. Other aspects of emotional and social behaviour affected by amygdala pathology in epilepsy have been recently reviewed in another issue of this journal [1].

Emotion recognition after bilateral amygdala lesion

Many studies have investigated the effect of bilateral amygdala damage on the ability to recognize emotion in faces. One of the first classical studies reported the case of a patient with complete bilateral amygdala destruction due to Urbach-Wiethe disease [2, 3], a rare disorder with progressive calcification and necrosis of the amygdala. This patient was tested by probing her ability to match expressive faces with corresponding emotion labels and to recognize similarity of expressions displayed by different faces. This patient showed a disproportionate impairment in recognizing fear in facial expressions, and only a much milder impairment in recognizing the intensity of other negative emotions (Figure 2). She had no other problems in recognizing other facial attributes, such as identity, age, or gender. These findings were interpreted as supporting the existence of a specific neural system for recognizing stimuli signalling danger. Lesion to the amygdala could induce fear recognition deficit because this brain structure is a key component within this system and its lesion may therefore disrupt the recognition of fear-related signals, including face expressions. These findings were subsequently confirmed by other studies using different tests in patients with other aetiologies of

amygdala damage [4, 5].

To determine whether such impairment could arise independently from aetiology, another study [6] investigated emotion recognition ability in nine patients with bilateral amygdala damage following herpetic encephalitis (in 8 cases) or congenital disease (in 1 case). This study used the same paradigm than the one given to the previous single patient [2]. Pictures of six individual faces expressing six basic emotions and three neutral faces were shown to the subjects who had to rate (on a scale from 0 to 5) the intensity of each of six emotions separately. The performance of amygdala patients was compared with that of patients with lesions other than the amygdala, as well as with healthy control subjects. Results revealed a similar response pattern in both the healthy and brain-damaged control groups. By contrast, patients with bilateral amygdala damage showed a very different pattern, with normal ratings for happy faces only, but abnormally low ratings for all negative emotions, especially for fear. However results also showed a substantial variability between patients (see table 2 for a summary of results).

Thus, although recognition of fear is generally the most impaired, this deficit is often not selective. Amygdala patients may be impaired for other emotions as well. It has been proposed that fear may be particularly hard to recognize in faces, relative to other more distinctive expressions [7]. Another systematic lesion study compared the performance of unilateral and bilateral amygdala-damaged patients on an emotion recognition test, with the performance of patients with unilateral and bilateral lesions in various brain regions other than the amygdala, as well as with normal subjects. This study found significant impairments in the recognition of fear for all patients groups, but no significant differences between the two patient groups (amygdala and non-amygdala damage). More interestingly, the authors reported that fear was the most poorly recognized emotion, relative to other facial expression, for both the patients and the normal subjects. These results imply that perceptual difficulty might be an important factor in determining disproportionate fear recognition deficits in many neurological patients, irrespective of the presence of amygdala lesions. However, these provocative findings have been questioned by other researchers. The test used by Rapcsak et al. [7] was a labelling task where the subjects were requested to match a facial expression with one of the six basic emotions. The analysis of errors revealed that fear was frequently identified as surprise but Adolphs et al. [8] proposed that in this test all choices are not equally distinct because fear and surprise can be considered as two forms of a subordinate category defined as general surprise. According to Adolphs et al. [8], if the surprise label was substituted with happy surprise the accuracy in recognizing fear would increase because labels for fear and surprise would be more distant. The authors interpreted the findings of Rapcsak et al. [7] as an effect

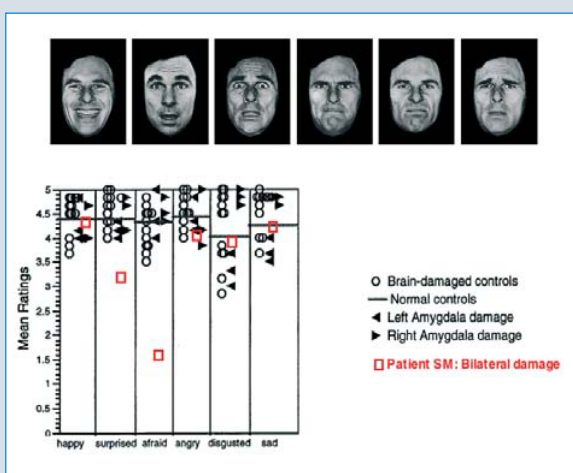


Figure 2. Illustration of different facial expressions used to test emotion recognition and performance of patient SM with bilateral amygdala lesion. Adapted from [3].

Table 2

Variability in the performance of different amygdala-damaged patients. Numbers indicate standard deviations below the mean of control patients with other sites of brain-damage, for the recognition of each emotion category on a task requiring to match facial expressions with their prototypical label. Adapted from [6].

<i>Patients</i>		<i>Emotional expressions</i>					
		<i>Happy</i>	<i>Sad</i>	<i>Disgusted</i>	<i>Angry</i>	<i>Afraid</i>	<i>Surprised</i>
SE	Encephalitis			-0.6	-0.8		-2.8
DR	Surgical		-3.1	-2.0	-5.5	-2.3	-4.4
EP	Encephalitis		-1.2		-4.3	-0.3	-1.2
GT	Encephalitis	-0.1			-0.2		
DBB	Surgical	-0.9	-1.2		-0.2	-1.5	
SM	Congenital	-1.3		-0.6	-0.8	-7.2	-3.3
RH	Encephalitis		-0.3		-4.3	-0.7	-0.7
SP	Lobectomy	-0.9	-2.8	-3.2		-6.4	
JM	Encephalitis		-2.2	-2.3	-5.5	-3.6	

of the ambiguity of the specific test used rather than a more general effect of difficulty in recognizing fear.

Another factor that may account for the variability of performance across patients is the duration of illness and/or age at onset. It is indeed plausible that an early onset of amygdala dysfunction could influence emotion recognition ability differently than other pathologies with later onset. In particular, Urbach-Wiethe disease is a congenital and progressive disorder, as opposed to other pathologies acquired during adulthood such as encephalitis herpetic. It is possible that patients with early pathology could develop compensatory strategies to recognize facial expressions; or alternatively they could fail to acquire critical skills for efficient emotion recognition.

This developmental hypothesis has been proposed to explain the different results found in some patients suffering from herpetic encephalitis [9]. It has been reported that such patients with amygdala damage due to encephalitis may show a normal ability to give verbal labels to emotions in faces [9] and to recognize the similarity of emotions expressed by different faces [10], unlike patients with Urbach-Wiethe disease [2, 3]. However, these results are not definitive because other authors have reported significant deficits in fear recognition in patients with amygdala damage after herpetic encephalitis [11]. As the aetiology of lesions in the latter study [11] was the same as in the previous study by Hamann et al. [9], a simple developmental hypothesis does not seem sufficient. Conversely, a recent study [12] in patients with Urbach-Wiethe disease, presumably associated with early and bilateral destruction of amygdala, reported that these patients performed normally on emotion recognition tests with faces. The only significant deficit found in these patients was a tendency to recognize more frequent “blends” between different facial expressions, relative to normal controls; that is, patients were more inclined to judge a fearful face as displaying both fear and disgust, or an angry face as displaying both anger and surprise. These results contrast

with previous findings [2, 3, 6] and suggest that amygdala damage consequent to Urbach-Wiethe disease may not necessarily produce disproportionate impairments in the recognition of specific facial emotions. Even though this is a congenital disorder starting early in life, its progression rate and severity may still vary substantially across patients. Moreover, the tests used to assess emotion recognition abilities varied between these different studies, and the nature of the instructions given to the patients was shown to affect the performances in recognition tasks [13]. In any case, it still remains unclear how to explain such variability in the effects of bilateral amygdala damage on emotional face recognition.

Dissociation between perception and production of emotional expressions

Recognition of emotion from faces can be impaired independently from other emotion processing abilities, including the production of emotional expressions in response to appropriate cues or on demands. Anderson and Phelps [14] reported the case of a patient who showed a dissociation between deficits in emotion recognition from pictures of faces and intact ability to produce the corresponding expressions on her own face.

This patient had received a right temporal lobectomy including amygdala for treatment of drug-resistant temporal epilepsy, but also presented an additional lesion of the left amygdala evidenced before lobectomy. Anderson and Phelps [14] first evaluated the patient’s ability to identify emotions from facial expressions using an emotion-labelling paradigm: a face expressing one of six basic emotions (fear, anger, disgust, sadness, joy, surprise) or with a neutral expression was presented together with a list of terms defining each of the six emotion categories, which the patient had to choose to describe the current facial expression shown. For this test, the patient showed a severe deficit in emo-

tion recognition. Recognition of fear was the most impaired, but disgust and sadness were abnormal too, with happiness showing the least severe problems. Thus, this impairment was not selective to fear, unlike in some other patients [2, 5, 11], but damage was extensive and not selective to the amygdala, with substantial involvement of other brain regions. In addition to the usual visual recognition tasks, the production of emotional expressions was also assessed in this patient by asking her to pose one of same six basic emotions. To perform this production task, the subject was instructed to think of an event who could make her feel the target emotion and to produce the corresponding facial expression that would be appropriate in such context. The expressions produced by the subject were videotaped and then showed to four judges who were asked to rate the correctness of each expression with respect to the target emotion. Healthy controls were examined in a similar manner. The evaluation of judges showed that facial expressions produced by the amygdala patient did not differ from those produced by healthy control subjects, for all of the six emotion categories.

These findings reveal that despite a severe deficit in recognizing emotion from faces, this patient was still able to express each basic emotion appropriately. The authors proposed that such dissociation might be consistent with an innate ability in producing non-verbal signals through facial expressions [15], and the well-established function of amygdala in emotional memory [16]. Thus, the ability to produce facial emotional expression may not be mediated by the amygdala because it relies on “pre-wired” motor programmes, whereas the ability to associate emotional meanings to seen expressions may be acquired through learning and experiences. Hence, early damage to the amygdala could impair the development of an adequate capacity for emotion recognition from faces but not impair the capacity to express emotions in the face.

In summary, we can conclude that bilateral amygdala damage often leads to selective deficits in facial emotion recognition, which may concern fear more frequently and severely than other emotions; but these deficits are not always present, depending on other factors that remain to be more fully understood, and they do not extend to impairments in expression production (including fear). Critical clinical factors influencing the pattern of emotional deficits are related to the aetiology of lesion and age of disease onset.

Face emotion recognition after unilateral amygdala lesion

Severe emotion recognition deficits have been more rarely observed in patients with unilateral amygdala lesions. These deficits may also be more variable and milder than those associated with bilateral pathology, due to compensatory mechanisms or aetiology differences.

The most common cause of unilateral amygdala damage is temporal lobe epilepsy (TLE). TLE is a frequent type of focal epilepsy, typically associated with mesial temporal sclerosis, with neural loss and gliosis involving the hippocampus, entorhinal cortex, and amygdala complex. Such sclerosis can lead to significant disruption of hippocampal and amygdala functions. In addition, because mesial temporal epilepsy presents with a strong risk of drug resistance, a common and effective therapy involves temporal lobectomy, with the removal of a variable extent of amygdala and hippocampus. Therefore, in TLE patients, unilateral damage to the amygdala may occur either before or after surgery, and in addition vary with the extent of surgery (either lobectomy or selective amygdalo-hippocampectomy). Primary amygdala damage to sclerosis is present in ~30% of patients with hippocampal sclerosis, and may occur alone (without hippocampal sclerosis) in ~10% of patients [17].

Meletti et al. [18] have recently investigated facial emotion recognition abilities in a sample of patients with temporal and extratemporal lobe epilepsy. They first compared the performance on facial emotion-label matching test across three groups of patients with different lesion characteristics: temporal lobe epilepsy with mesial temporal sclerosis, temporal lobe epilepsy with evidence of other lesion aetiology, and extratemporal lobe epilepsy. Results revealed that patients with right-side mesial temporal sclerosis were impaired in the recognition of all emotions as compared with other groups (Figure 3). Nevertheless, an analysis of each emotion category showed that recognition of fear was the most severely impaired ability. These data indicate that unilateral right amygdala damage is sufficient to cause deficits in facial expression recognition.

The same authors [18] also analyzed the patients' performance in relation to several clinical variables such as the age of first seizure and epilepsy onset. Early onset was arbitrarily defined as seizures starting before five year-old, and late onset as seizures starting after five year-old. They found that an early onset correlated with a greater severity of emotion recognition impairments. These findings are particularly interesting because they suggest that emotion recognition abilities may be impaired even before lobectomy, but vary across patients based on their history. Both the age of onset and side of temporal epilepsy seem to predict the degree of deficit, with right-sided amygdala pathology and seizures before 5 year-old leading to more severe problems in fear recognition. These findings were supported by two other subsequent studies [19, 20].

Taken together, these data clearly indicate that emotional disorders due to temporal lobe lesions and amygdala dysfunction may be modulated by aetiological and developmental factors. Remarkably, amygdala dysfunction present during an early critical period in life may have particular detrimental consequences on subsequent emotional and social processes, perhaps because

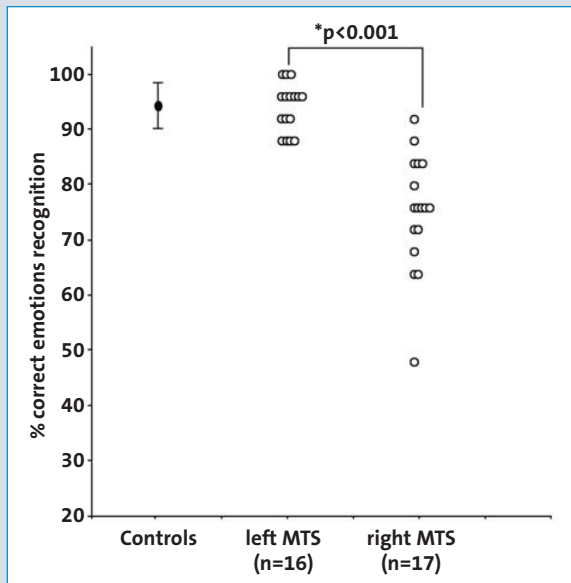


Figure 3. Face expression recognition (pooled across emotions) in patients with temporal lobe epilepsy (TLE). Adapted from [18].

of intimate links between medial temporal lobe structures and learning. This stands in sharp contrast with other neurological disturbances due to early brain injuries, which often tend to have better prognosis than similar injuries occurring later in life, such as those affecting motor or language abilities.

Emotion recognition after surgical lobectomy

Studies involving patients with amygdala lesions following temporal lobectomy (or more selective amygdala-hippocampectomy removal) have also reported mixed and somewhat conflicting results. Some studies found that unilateral temporal lobectomy patients do not show any deficit in the recognition of emotional faces [3]. Other studies reported some impairment in fear recognition after lobectomy, but attributed such deficit to more general cognitive decline or task difficulty because other patients group (without amygdala damage) showed a similar deficit [7] on the same tests. A more recent study partially confirmed these findings [21]. In the latter, emotion recognition ability was examined in both left and right temporal lobectomy patients, and only a minority of these patients showed a significant difficulty. No difference was found between left and right amygdala damage [21].

However, it must be noted that these studies have usually not considered the possible influence of the aetiology of epilepsy and other clinical factors preceding surgical lobectomy. In particular, we have no information about the onset of seizures in these patients, and it is possible that some differences in the developmental history of their pathology might explain the absence or variability of emotion recognition deficits in some cases.

Accordingly, the hypothesis of an important correlation between early onset and severity of emotional impairments, as proposed by Meletti et al. [18] for TLE patients prior to surgery, was also verified in a group of patients with amygdala damage caused by lobectomy [20]. In this study, the authors examined emotion recognition in early-onset patients (before 5 year-old) and late-onset patients (after 5 year-old) who all had received right temporal lobectomy. Results showed that only early-onset patients were strongly impaired in recognition of fear, whereas late-onset patients were not significantly different from control subjects.

These findings support the hypothesis that early-onset patients with right amygdala damage presented a deficit in fear recognition even before lobectomy, and suggest that such deficit may simply persist after surgery. Nevertheless, lobectomy also involves the removal of a varying extent of surrounding cortex. It is likely that this may produce additional damage and corresponding changes in neuropsychological performance, but this issue still remains to be more systematically investigated.

Implicit emotion processing

Most of the deficits described above have examined the effect of amygdala lesion on tasks requiring explicit recognition of emotional expression in faces. However, emotion perception usually arises during conditions when emotion recognition is not directly required by task demands and may also arise even when the stimulus is not consciously perceived by the observer.

Only a few studies have tested whether patients with amygdala lesion might still show intact ability in implicit emotion processing [22, 23], even when they fail on more explicit tasks. For instance, it has been reported that emotion expression can facilitate implicit memory for faces in a repetition priming test. Priming is a type of implicit memory that is characterized by unintentional retrieval or automatic influences of previously acquired information on a memory test that does not require conscious or explicit recollection of the previous experience with the same stimuli [24]. The effect of emotion on repetition priming was investigated by Burton et al. [22, 23] in patients with left and right lobectomy including the amygdala. These authors assessed indirect perception and priming of emotional and neutral facial expressions in two phases. Patients were first presented with a series of photographs of faces that could express one of six different negative emotions (sadness, anger, fear, disgust, pain, and shock), seen with different head orientation and different lighting conditions. In the second phase, patients were now presented with pairs of photographs in which one was from the first phase and the other was new. Patients were requested to indicate which of the two faces had already been presented in the first phase. Results revealed that patients were more accurate and rapid in identifying the old emotional faces

than the neutral ones. Moreover, patients with left and right temporal lobectomy showed different effects, with the left-side patients showing a stronger facilitation on both accuracy and response times for the affective stimuli [23]. Although this study used only negative emotions, a similar implicit facilitation effect has been observed in another study with positive emotions [22]. These data therefore suggest that unintentional processing of emotion expression may still take place and influence face recognition memory in lobectomy patients, but such residual effects may exist in left-side patients and not be entirely intact in right-side cases. Unfortunately, explicit recognition of face expressions was not systematically tested in these studies.

Another study investigated implicit emotion processing using an affective priming paradigm [25]. In this test, evaluation of the emotional valence (either positive or negative) of a stimulus is normally faster when the stimulus is preceded by a prime with the same valence, rather than by a prime with opposite valence. Patients with left and right temporal lobectomy including amygdala and hippocampus were tested on a priming task in which the prime stimulus (a face expressing a negative or positive emotion) was briefly presented (for 250 ms) prior to a target stimulus (which was either congruent or incongruent with the prime). Patients were asked to judge the affective connotation of target faces (positive or negative) as fast as possible. Results showed that patients were generally slower to respond than healthy control subjects, but nevertheless faster in congruent trials than incongruent trials, just as were the healthy control subjects. Unlike in the previous study [23], no difference was found between patients with right left temporal lobe lesion.

Altogether, these findings suggest that unilateral lobectomy lesions implicating the amygdala may not be sufficient to impair some automatic and implicit forms of processing for emotional stimuli. It is possible that some automatic evaluation of affective valence may be performed via other mechanisms or via compensation by other brain regions. However, expressive faces are also characterized by distinctive facial features, and it remains unclear whether such indirect or implicit effects in priming task reflect true emotional processing or more elementary visual analysis. For instance, amygdala damaged patients can perform well on perceptual tasks emphasizing feature analysis, such as sorting morphed faces from one morph to the other one along a neutral-emotional continuum [26]. Thus, both visual and emotional factors might potentially contribute to implicit expression recognition abilities.

Neural circuits for emotional face processing

What are the possible neural substrates underlying the different deficits in emotion recognition across patients, and possibly the different compensation mechanisms that may come into play at different ages in life?

Processing face identity and face expression has long been known to rely on partly distinct brain systems, as indicated by neuropsychological dissociations between patients with severe impairments in one but not the other ability. However, more recent investigations combining lesion and imaging approaches (such as EEG, PET, and fMRI) have begun to indicate that strong functional interactions may exist between brain areas implicated in different stages of face processing [27]. These interactions may play an important role in modulating the clinical manifestations and/or developmental deficits in emotion recognition in patients with temporal lobe pathology and epilepsy.

Current neurocognitive models of face processing in humans [28, 29] assume that the early visual analysis of facial features important for face detection and identification takes place in specialized areas within occipital and temporal cortex, including in particular the fusiform gyrus (fusiform face area, FFA). In parallel, the visual analysis of changeable features associated with expression or gaze information implicates different areas in superior temporal sulcus (STS), whereas emotional evaluation itself implicates other regions within the limbic system including amygdala and orbitofrontal cortex (**Figure 4**). Importantly, however, there is both anatomical and functional evidence that emotional processing in the amygdala can modulate face processing in distant regions, including both STS and FFA [30, 31]. Such influences may play a critical role in enhancing the perception and memory of faces with emotionally salient expressions, but it remains an open question whether during early development they may also contribute to shape functional selectivity and response sensitivity of cortical areas responding to faces such as the FFA [32].

Only a few studies have used fMRI in patients with temporal lobe epilepsy and amygdala lesions. Such functional imaging studies allow not only direct identification of amygdala dysfunction [33] but also provide precious insights on more distributed activation patterns that may be abnormal in these patients due to remote effects of medial temporal lobe damage.

In a recent study [19], fMRI was performed in a group of temporal lobe epilepsy patients with either left or right amygdala damage to examine brain responses to pictures of fearful and neutral faces. Consistent with previous findings, right amygdala-damaged patients with early-onset of seizures were the most impaired in recognizing fearful expressions in faces. Moreover, fMRI results converged with this behavioural pattern by demonstrating distinct patterns of neural activation to fearful faces depending on the lesion side. Left temporal lobe epilepsy patients and healthy control subjects showed bilateral activation in mesial temporal lobe including amygdala, but in the right temporal lobe patients this mesial temporal activation was restricted to the left hemisphere [19]. Another fMRI study reported that control subjects and patients with left temporal lobe epilepsy showed activation to fearful faces in a network of re-

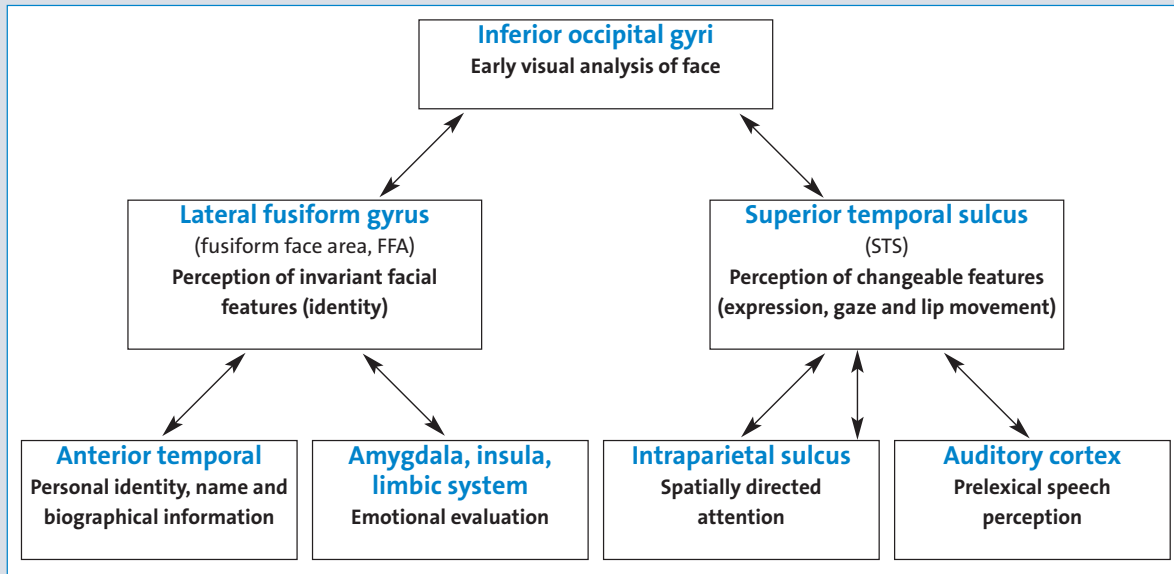


Figure 4: Neurocognitive models of face recognition mechanisms in the human brain. Adapted from [28].

gions including occipital and frontal cortical areas as well as right amygdala, whereas this amygdala activation was not found in patients with right temporal lobe epilepsy who failed in recognizing fearful faces [34]. These data are consistent with a dominant role of the right hemisphere and right amygdala in processing faces and facial expressions.

Other fMRI results in patients with mesial temporal sclerosis further demonstrate that amygdala lesions (but not hippocampal lesions) produce important changes in brain responses to fearful faces, with selective impact on ipsilateral visual cortical areas [31]. Thus, while healthy subjects typically show greater activation to fearful than neutral faces in bilateral fusiform areas (FFA), right amygdala sclerosis was found to reduce the activation to fear in right but not left fusiform, and vice versa, left amygdala sclerosis reduced the activation to fear in left but not right fusiform.

Finally, fMRI results also suggest that emotional face processing may not only implicate different brain pathways but also rely on different information in visual inputs, which may be differentially affected by different brain lesions and thus possibly contribute to variable findings concerning the amygdala role in processing facial expression. In particular, a dissociation between cortical and subcortical visual pathways has been proposed in several studies involving both brain-damaged and healthy subjects. In a recent fMRI study [11], neural responses to emotional faces were compared for face stimuli with different spatial frequency (low or high). Amygdala responses were greater for fearful faces with low spatial frequencies; whereas fusiform cortex was more sensitive to high frequencies components, regardless of emotion expression. This result suggests that these two different pathways can convey face information but with different information contents, and thus mediate different aspects of emotion recognition (e.g. at implicit or explicit levels).

In normal situations, these two routes operate simultaneously, but damage to one of them might induce different patterns of impairment depending on task demands, possibility of compensatory strategies, and perhaps age at lesion onset. It is possible that early damage to the amygdala might induce a stronger recruitment of cortical pathway to compensate the lesion, as previously proposed to explain differences in emotion recognition ability between patients with bilateral amygdala caused by congenital disease and those with other aetiologies [5, 9]. On the other hand, early damage to the amygdala might also disrupt some modulatory influences on visual cortex during development which might be important to tune these visual areas to specific features associated with emotional expressions, especially when such lesions implicate the right hemisphere in which face processing is typically dominant. This hypothesis would be consistent with behavioural and imaging results observed in patients with early onset of unilateral right amygdala pathology [14].

Conclusion

It now seems to be clearly established that amygdala damage can impair recognition of emotional face expressions but that such impairment may vary considerably across patients and tasks. This suggests that other factors associated with amygdala pathology need to be present in order to disrupt recognition of emotions in faces. Both aetiology and time of onset of disease seem to have major influences on the type and severity of emotion recognition deficits. Right temporal lobe dysfunction starting early in life, presumably before 5 year-old, may produce more severe and persistent deficits affecting performance for different facial emotions and different task, perhaps most particularly for negative and fe-

arful expressions. These data underscore the importance of a more systematic assessment of affective and social functions in patients with temporal lobe epilepsy, before and after surgery, including in younger children. Future research should also compare more systematically the performance of patients on emotional tests before and after lobectomy, as this would help distinguish between pre-existing disorders and possible effects of surgery, ultimately allowing better prediction and understanding of the variable impairments in emotion processing that are frequently associated with temporal lobe epilepsy.

References

- Cristinzio C, Vuilleumier P. The role of amygdala in emotional and social functions: Implications for temporal lobe epilepsy. *Epileptologie* 2007; 24: 78-89
- Adolphs R, Tranel D, Damasio H, Damasio A. Impaired recognition of emotion in facial expressions following bilateral damage to the human amygdala. *Nature* 1994; 372: 669-672
- Adolphs R, Tranel D, Damasio H, Damasio AR. Fear and the human amygdala. *J Neurosci* 1995; 15: 5879-5891
- Young AW, Aggleton JP, Hellawell DJ et al. Face processing impairments after amygdalotomy. *Brain* 1995; 118(Pt 1): 15-24
- Calder AJ, Young AW, Rowland D et al. Facial emotion recognition after bilateral amygdala damage: differentially severe impairment of fear. *Cognitive Neuropsychology* 1996; 13: 669-745
- Adolphs R, Tranel D, Hamann S et al. Recognition of facial emotion in nine individuals with bilateral amygdala damage. *Neuropsychologia* 1999; 37: 1111-1117
- Rapcsak SZ, Galper SR, Comer JF et al. Fear recognition deficits after focal brain damage: a cautionary note. *Neurology* 2000; 54: 575-581
- Adolphs R. Recognizing emotion from facial expressions: psychological and neurological mechanisms. *Behavioral and Cognitive Neuroscience Reviews* 2002; 1: 21-62
- Hamann SB, Stefanacci L, Squire LR et al. Recognizing facial emotion. *Nature* 1996; 379: 497
- Hamann SB, Adolphs R. Normal recognition of emotional similarity between facial expressions following bilateral amygdala damage. *Neuropsychologia* 1999; 37: 1135-1141
- Broks P, Young AW, Maratos EJ et al. Face processing impairments after encephalitis: amygdala damage and recognition of fear. *Neuropsychologia* 1998; 36: 59-70
- Siebert M, Markowitsch HJ, Bartel P. Amygdala, affect and cognition: evidence from 10 patients with Urbach-Wiethe disease. *Brain* 2003; 126: 2627-2637
- Adolphs R, Gosselin F, Buchanan TW et al. A mechanism for impaired fear recognition after amygdala damage. *Nature* 2005; 433: 68-72
- Anderson AK, Phelps EA. Expression without recognition: contributions of the human amygdala to emotional communication. *Psychol Sci* 2000; 11: 106-111
- Darwin C. *The Expression of the Emotions in Man and Animals*. New York: Oxford University Press, 1998
- Ledoux JE. *The Emotional Brain*. New York: Simon & Schuster, 1996
- Pitkanen A, Tuunanen J, Kalviainen R et al. Amygdala damage in experimental and human temporal lobe epilepsy. *Epilepsy research* 1998; 32: 233-253
- Meletti S, Benuzzi F, Rubboli G et al. Impaired facial emotion recognition in early-onset right mesial temporal lobe epilepsy. *Neurology* 2003; 60: 426-431
- Benuzzi F, Meletti S, Zamboni G et al. Impaired fear processing in right mesial temporal sclerosis: a fMRI study. *Brain research bulletin* 2004; 63: 269-281
- McClelland S, 3rd, Garcia RE, Peraza DM, et al. Facial emotion recognition after curative nondominant temporal lobectomy in patients with mesial temporal sclerosis. *Epilepsia* 2006; 47: 1337-1342
- Fowler HL, Baker GA, Tipples J et al. Recognition of emotion with temporal lobe epilepsy and asymmetrical amygdala damage. *Epilepsy Behav* 2006; 9: 164-172
- Coppens E, Vansteenwegen D, Spruyt A et al. Automatic affective stimulus processing is intact after unilateral resection of the anterior temporal lobe in humans. *Neuropsychologia* 2007; 45: 431-434
- Burton LA, Wyatt G, Rabin L et al. Perception and priming of affective faces in temporal lobectomy patients. *J Clin Exp Neuropsychol* 2003; 25: 348-360
- Schacter DL, Cooper LA, Delaney SM et al. Implicit memory for possible and impossible objects: constraints on the construction of structural descriptions. *Journal of experimental psychology* 1991; 17: 3-19
- Klauer K, Musch J. Affective priming: findings and theories. In: Klauer C, Musch J (eds): *The Psychology of Evaluation: Affective Processes in Cognition and Emotion*. Mahway, NJ: Lawrence Erlbaum, 2003: 7-49
- Graham R, Devinsky O, LaBar KS. Sequential ordering of morphed faces and facial expressions following temporal lobe damage. *Neuropsychologia* 2006; 44: 1398-1405
- Vuilleumier P, Pourtois G. Distributed and interactive brain mechanisms during emotion face perception: evidence from functional neuroimaging. *Neuropsychologia* 2007; 45: 174-194
- Haxby JV, Hoffman EA, Gobbini MI. The distributed human neural system for face perception. *Trends Cogn Sci* 2000; 4: 223-233
- Haxby JV, Ida Gobbini M. The perception of emotion and social cues in faces. *Neuropsychologia* 2007; 45: 1
- Vuilleumier P, Armony JL, Driver J, Dolan RJ. Effects of attention and emotion on face processing in the human brain: an event-related fMRI study. *Neuron* 2001; 30: 829-841
- Vuilleumier P, Richardson MP, Armony JL et al. Distant influences of amygdala lesion on visual cortical activation during emotional face processing. *Nature neuroscience* 2004; 7: 1271-1278
- Grelotti DJ, Gauthier I, Schultz RT. Social interest and the development of cortical face specialization: what autism teaches us about face processing. *Dev Psychobiol* 2002; 40: 213-225
- Schacher M, Haemmerle B, Woermann FG et al. Amygdala fMRI lateralizes temporal lobe epilepsy. *Neurology* 2006; 66: 81-87
- Batut AC, Gounot D, Namer JJ et al. Neural responses associated with positive and negative emotion processing in patients with left versus right temporal lobe epilepsy. *Epilepsy Behav* 2006; 9: 415-423

Address for correspondence:

Prof. Patrik Vuilleumier

Lab NIC, Dept of Neurosciences & Clinic of Neurology

Centre Médical Universitaire (CMU)

1 rue Michel Servet | CH 1211 Geneva

Tel. 0041 22 3795 382 | Fax 0041 22 3795 402

patrik.vuilleumier@medecine.unige.ch