

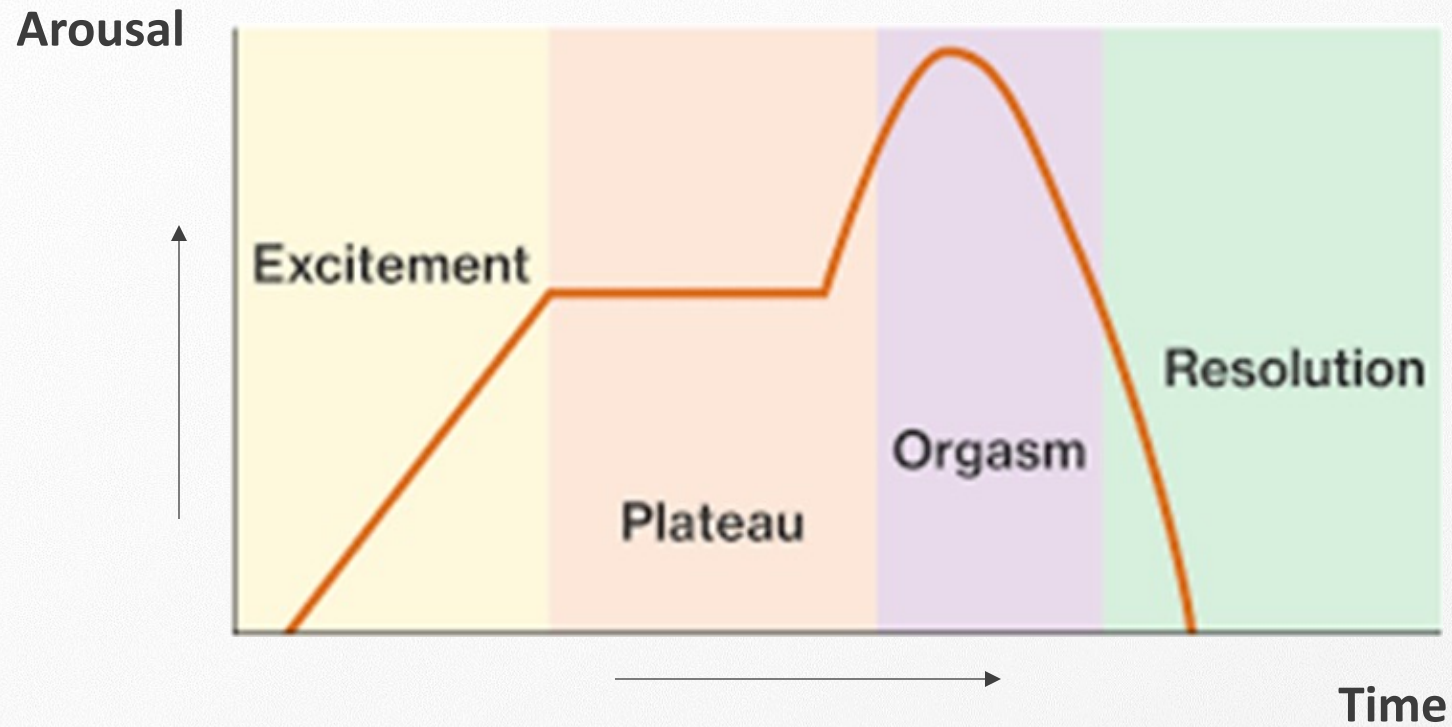
Anatomical and physiological bases of the sexual response

Leen Aerts, MD PhD PD

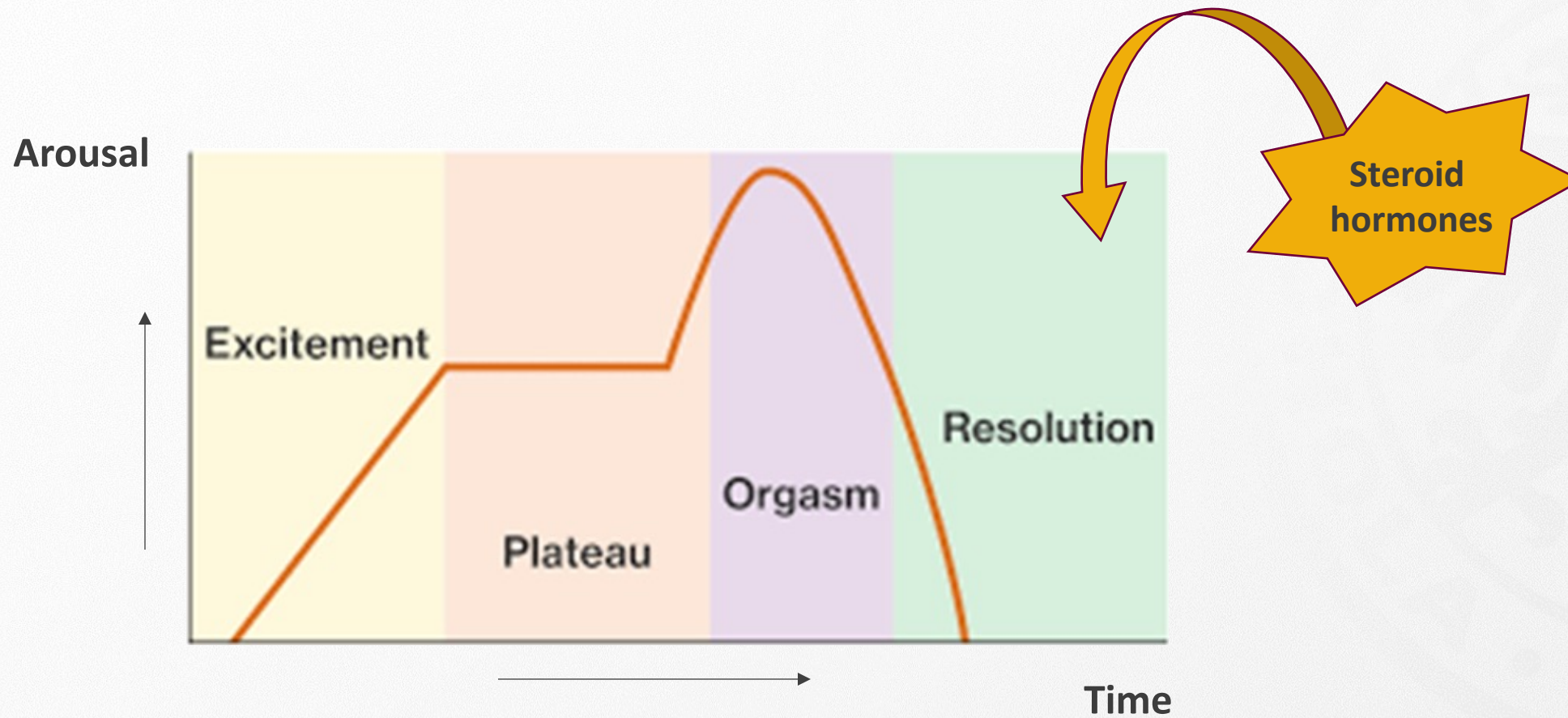
Ancienne médecin adjointe agrégée HUG

Cabinet privé Genève

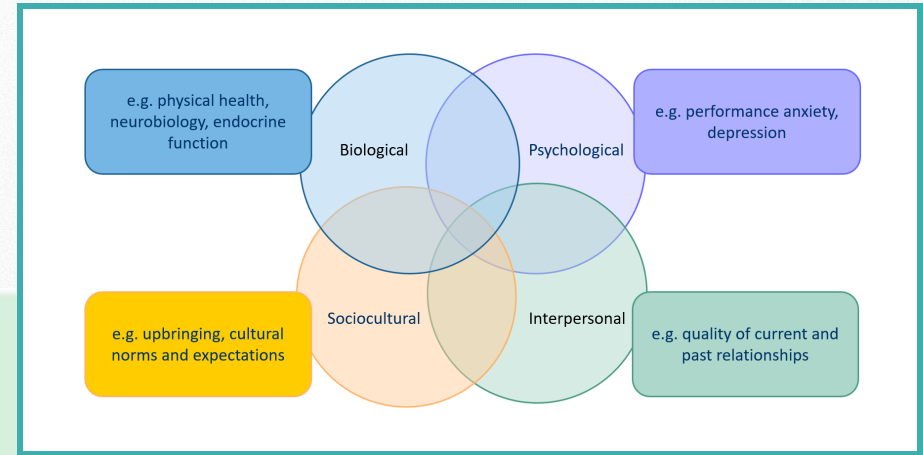
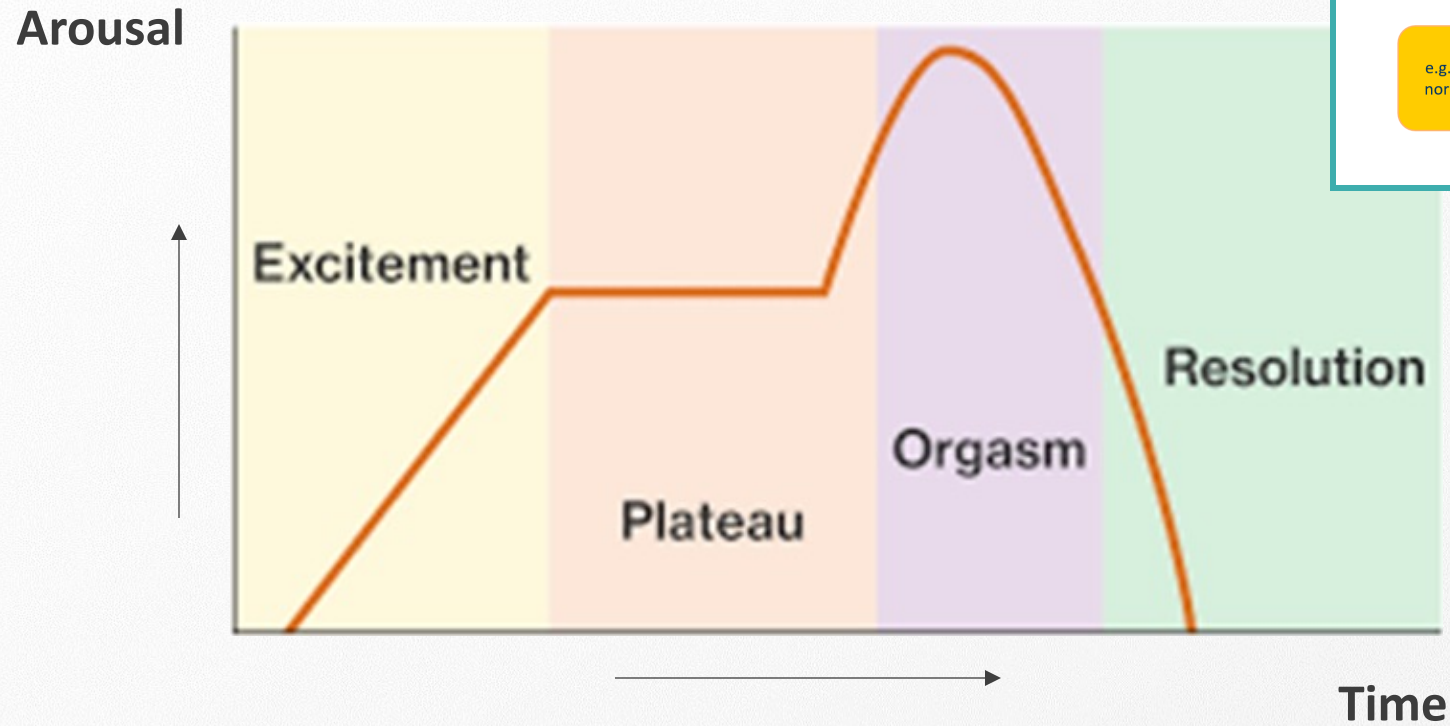
Bio-psycho-social model of sexuality



Bio-psycho-social model of sexuality



Bio-psycho-social model of sexuality



Anatomical and physiological bases of sexual response

A. Sexual anatomy and physiology

- ❖ Genital anatomy
- ❖ Pelvic floor muscles
- ❖ Genital vascularisation
- ❖ Central and peripheral nervous system

B. Physiological changes during sexual response

C. Steroid hormones and sexuality

Anatomical and physiological bases of sexual response

A. Sexual anatomy and physiology

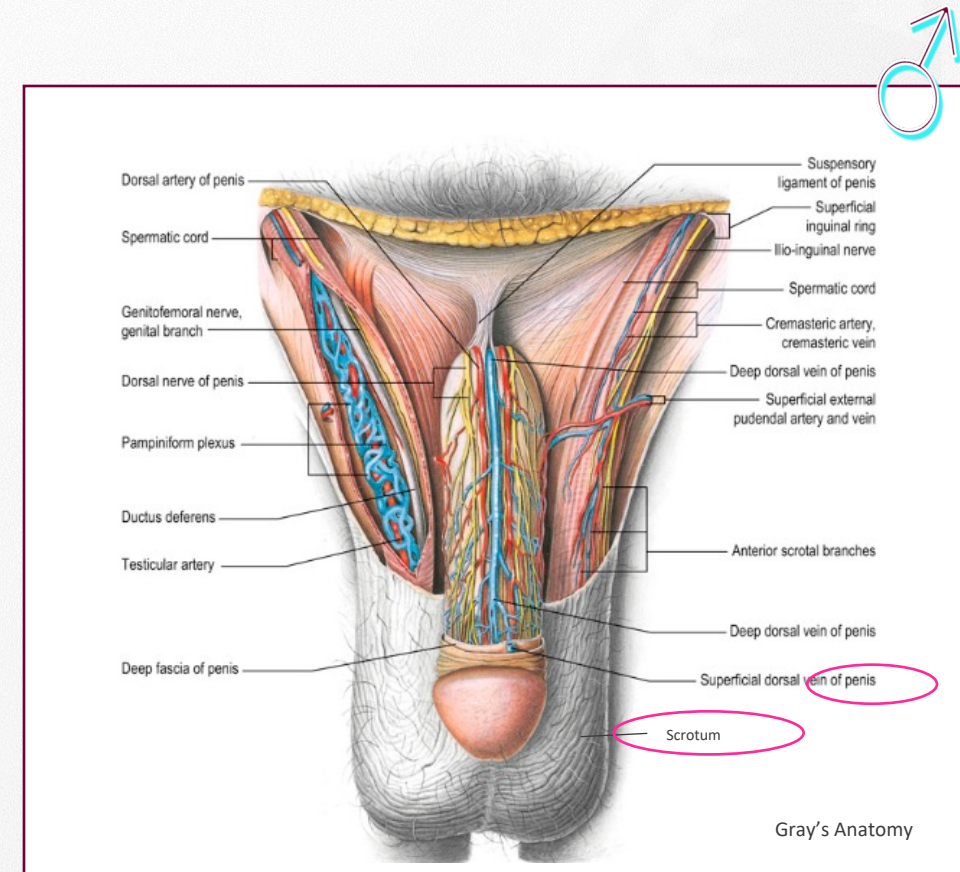
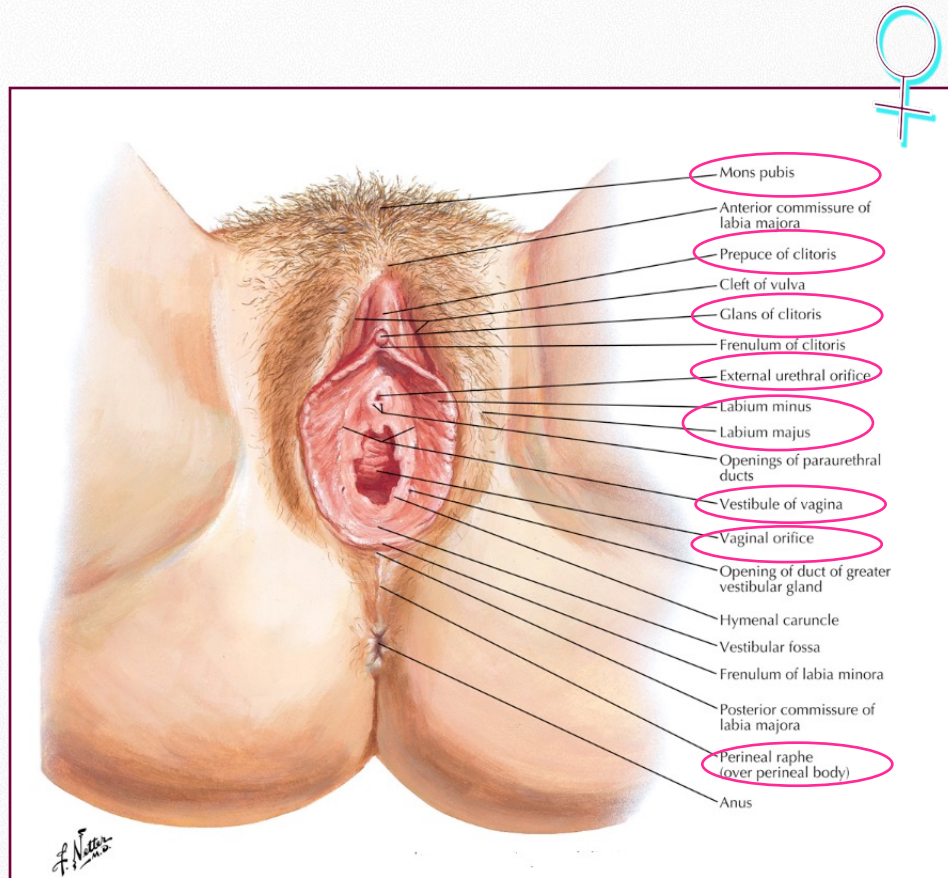
- ❖ Genital anatomy
- ❖ Pelvic floor muscles
- ❖ Genital vascularisation
- ❖ Central and peripheral nervous system

B. Physiological changes during sexual response

C. Steroid hormones and sexuality

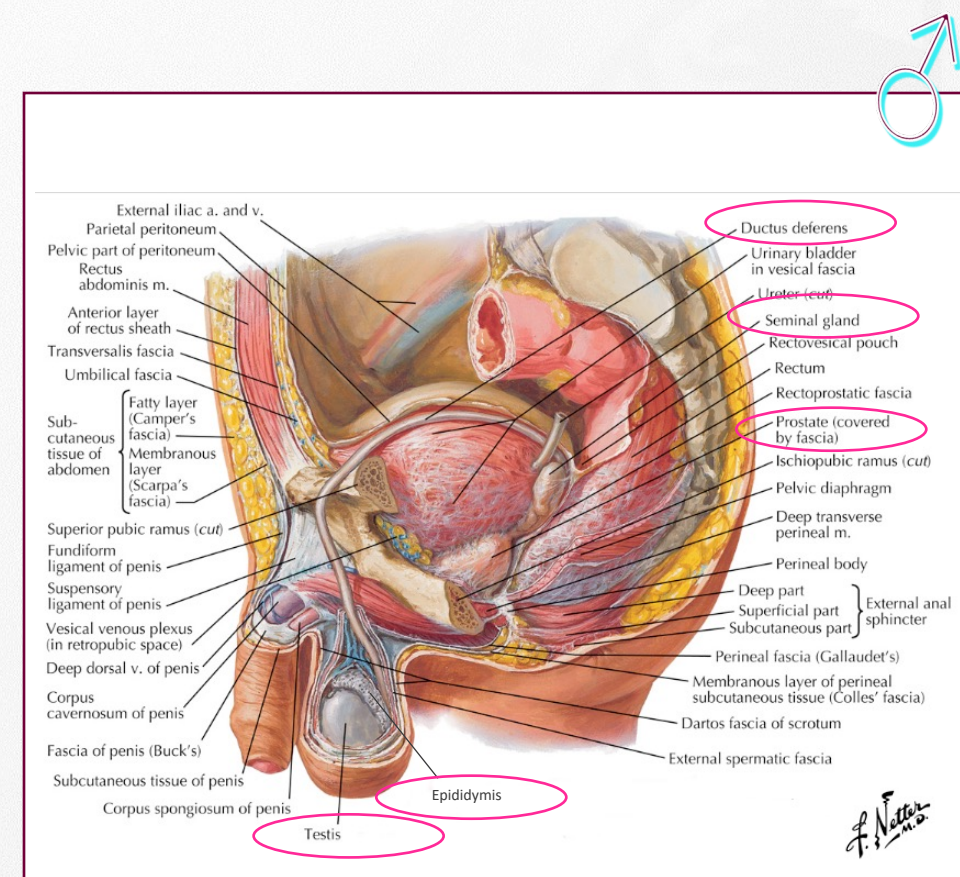
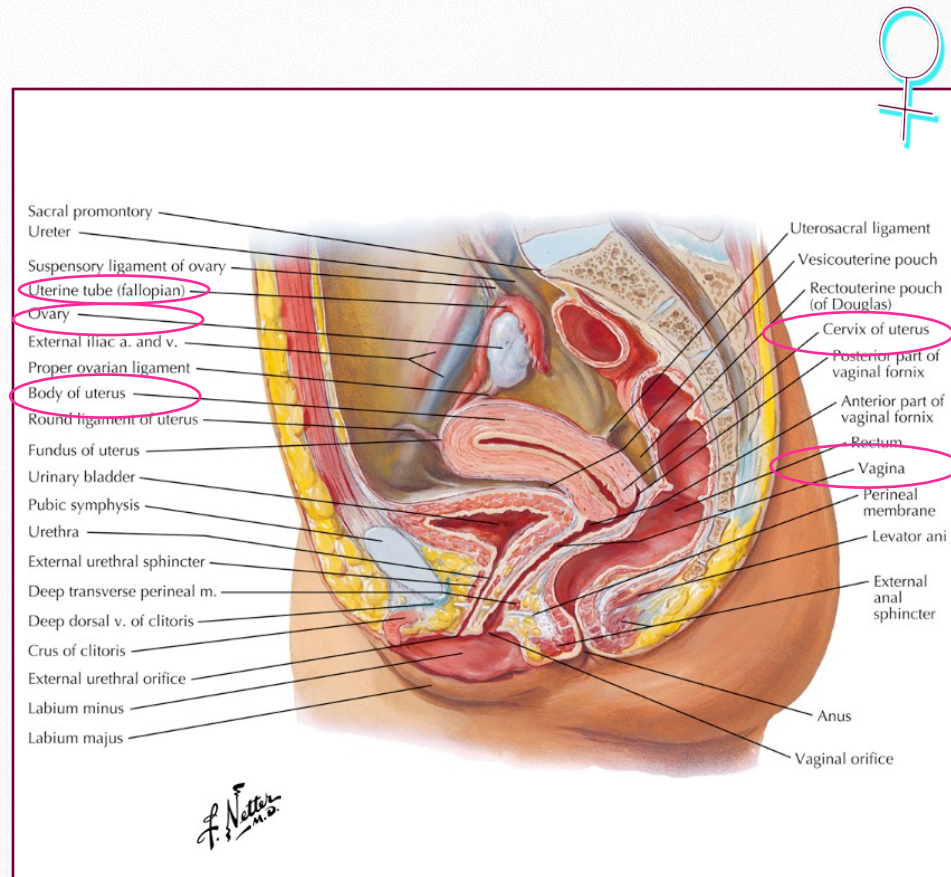
Sexual anatomy and physiology

❖ Genital anatomy



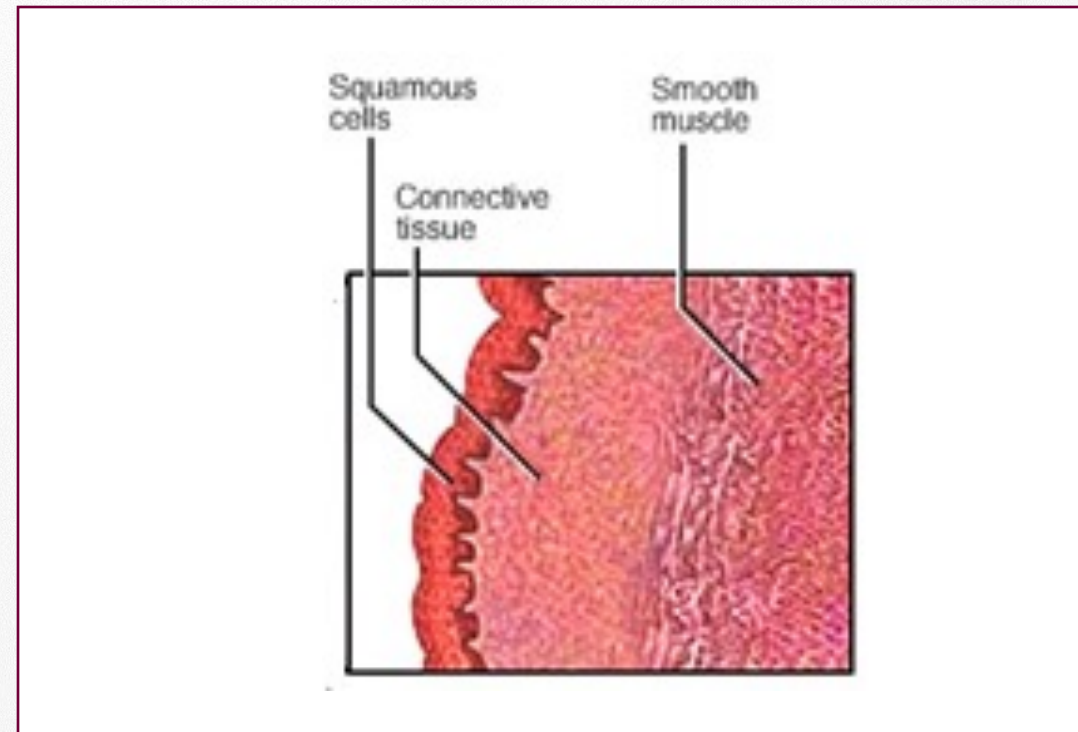
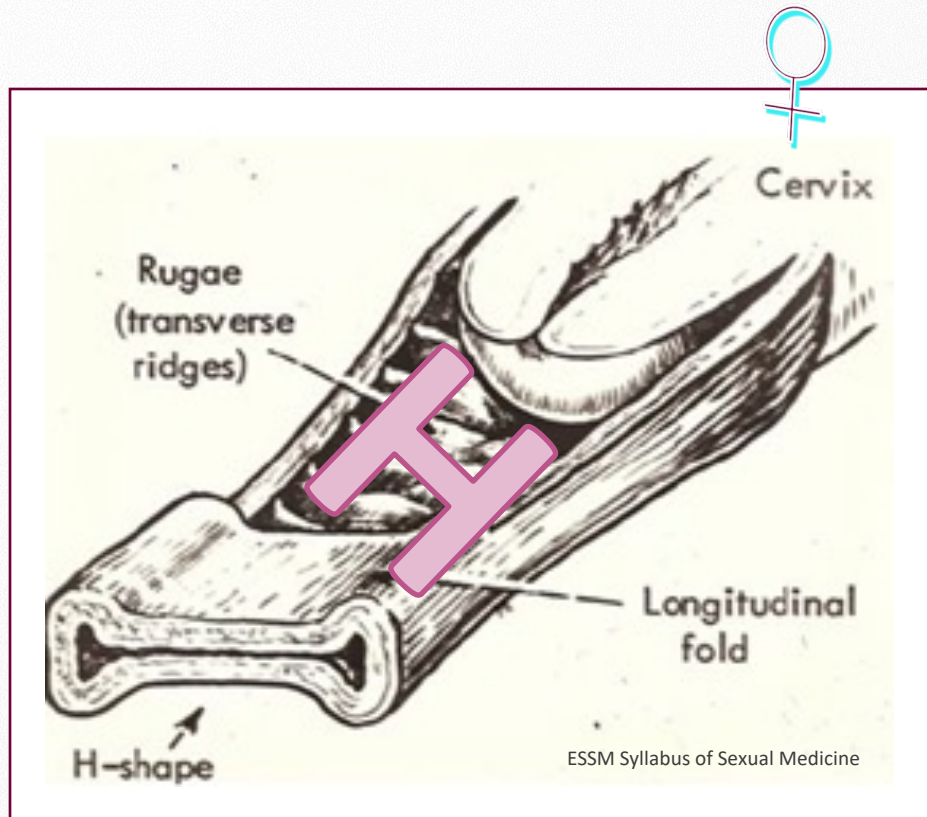
Sexual anatomy and physiology

❖ Genital anatomy



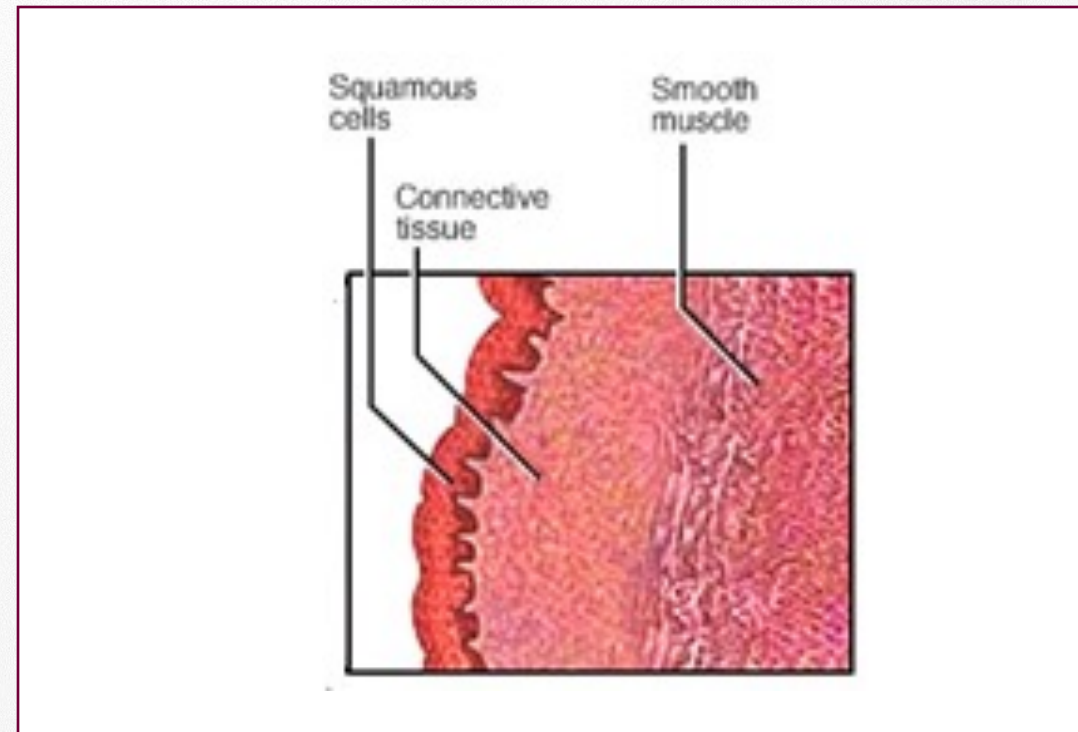
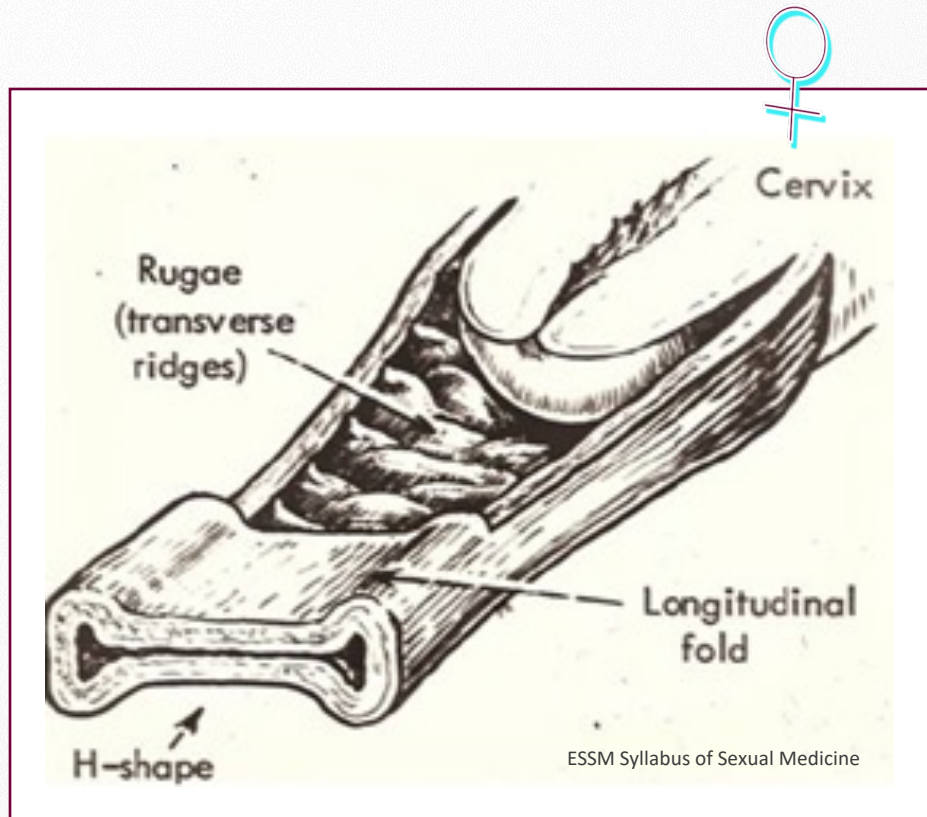
Sexual anatomy and physiology

❖ Genital anatomy



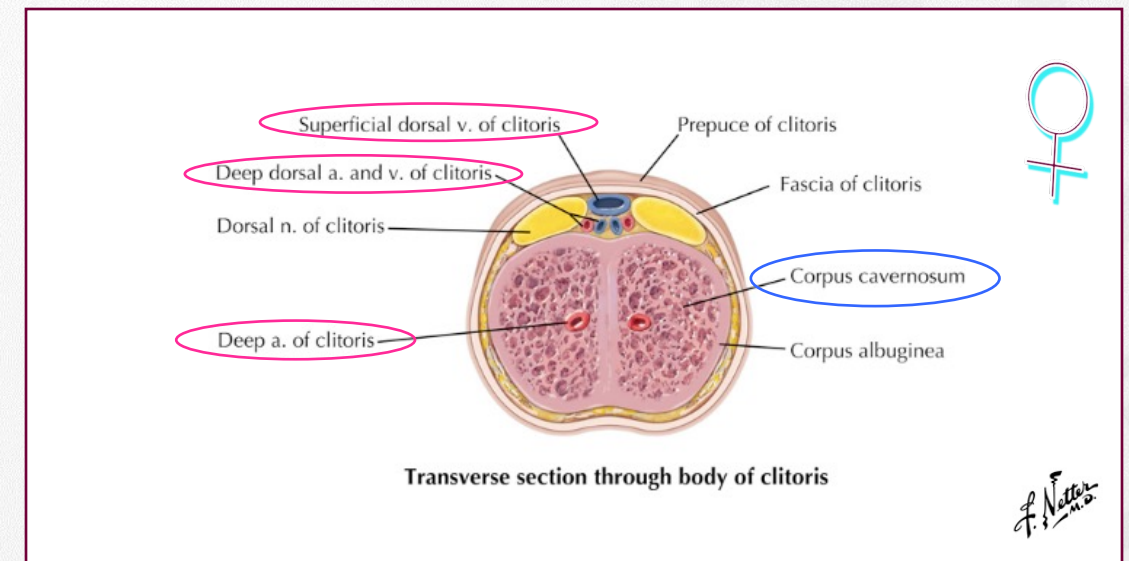
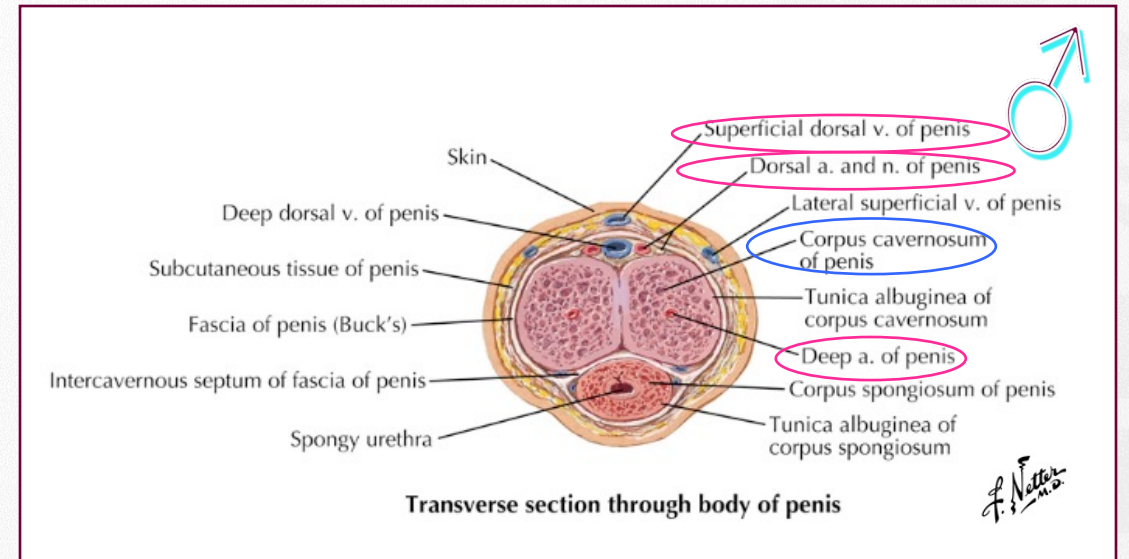
Sexual anatomy and physiology

❖ Genital anatomy



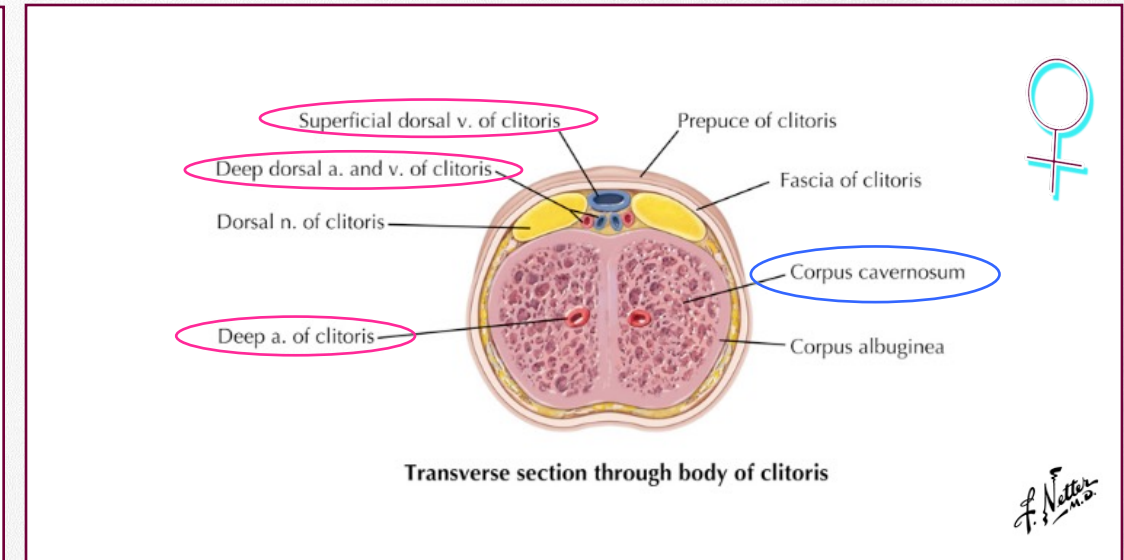
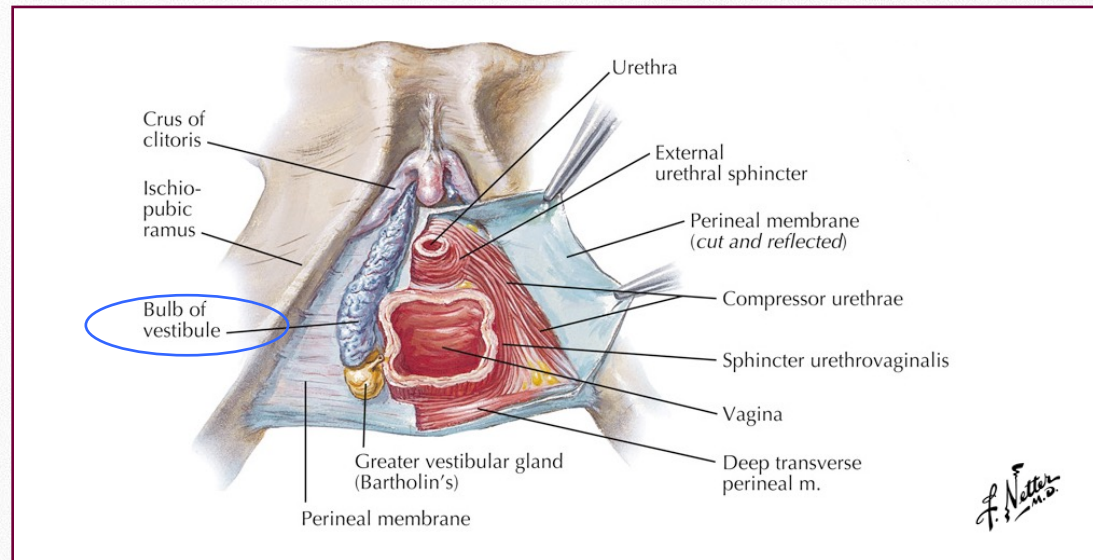
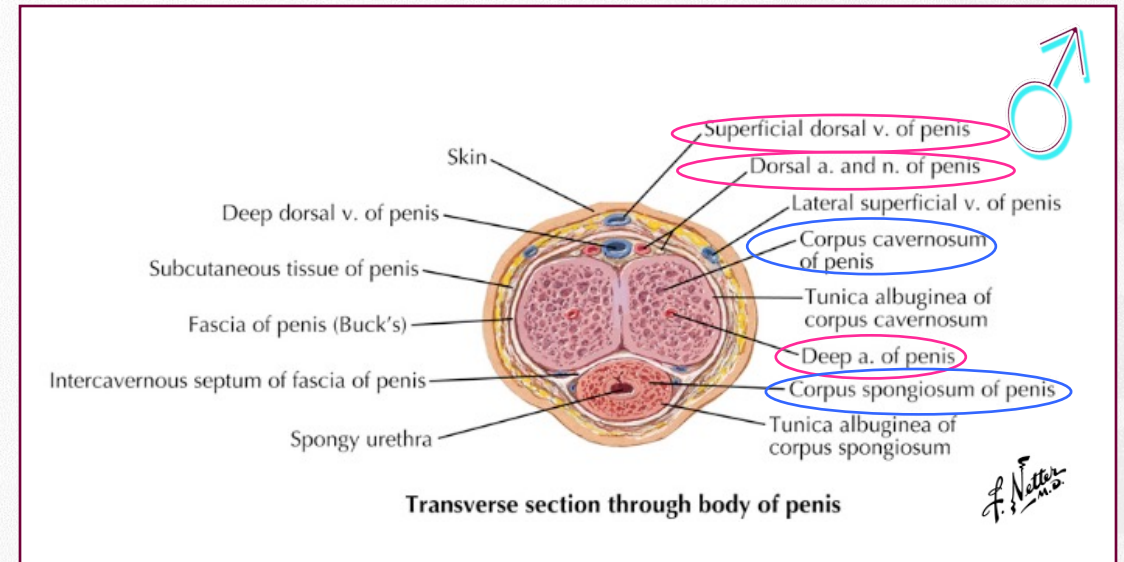
Sexual anatomy and physiology

❖ Genital anatomy



Sexual anatomy and physiology

❖ Genital anatomy



Sexual anatomy and physiology

❖ Genital anatomy

Clitoris-Urethra-Vaginal Complex

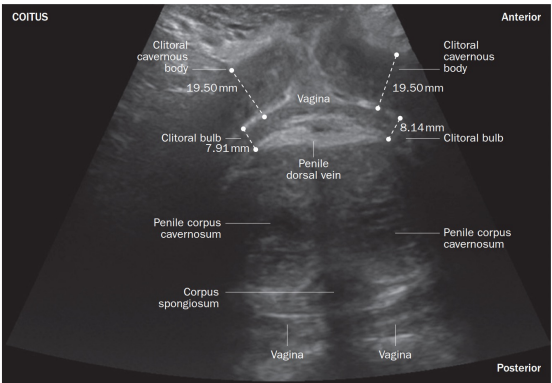
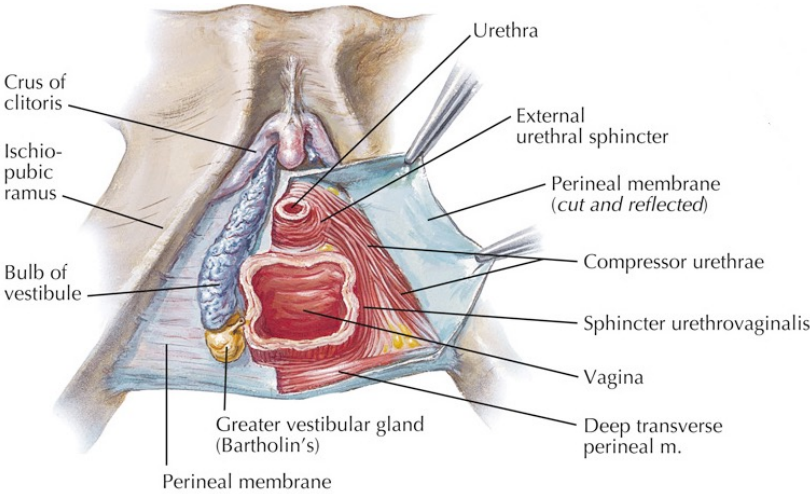
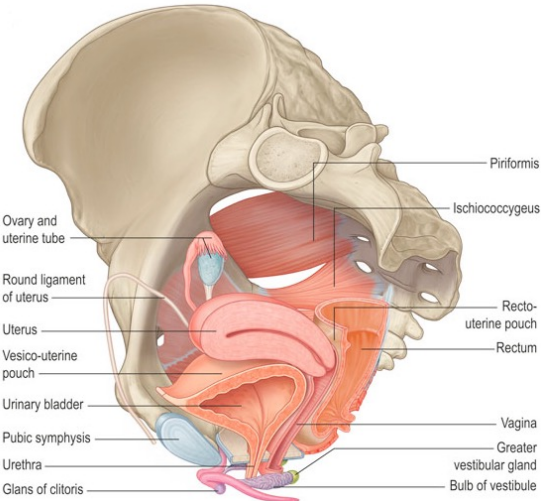
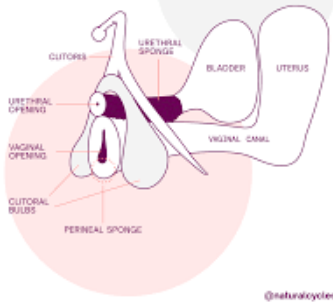


Figure 2 | Ultrasongraphic coronal plane image taken at the top of the vulva during coitus in a healthy nulliparous woman. The image obtained during vaginal penetration shows the close proximity of components of the clittourethrovaginal (CUV) complex, specifically the clitoral bulbs and cavernous bodies, and the vaginal wall. Dynamic echography demonstrated that the CUV complex is stretched and stimulated by the penis during coitus. This observation suggests that such stimulation of the CUV complex could contribute to the attainment of vaginally activated

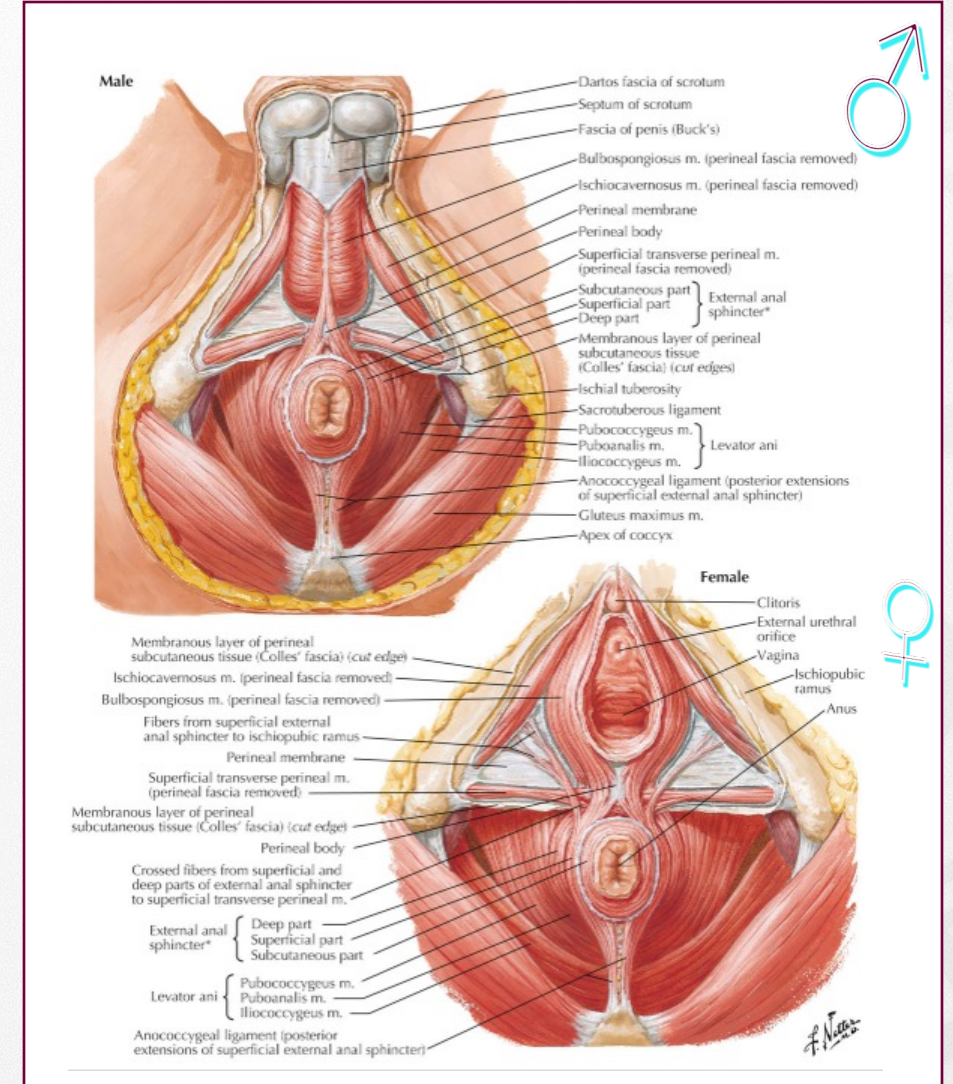
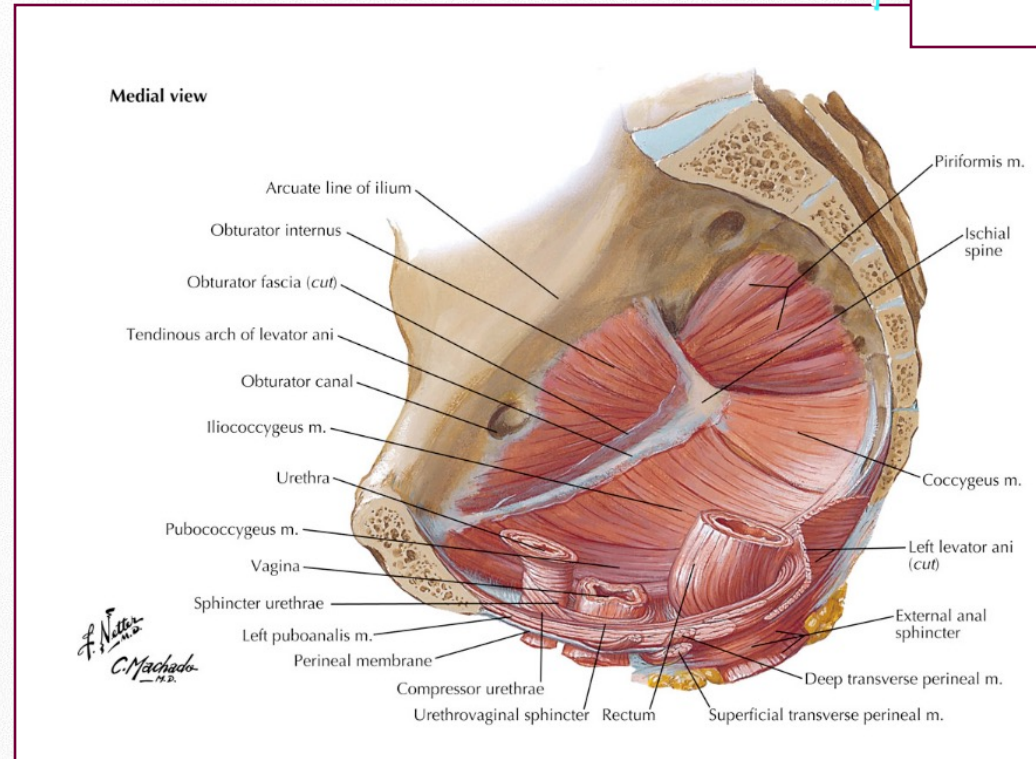
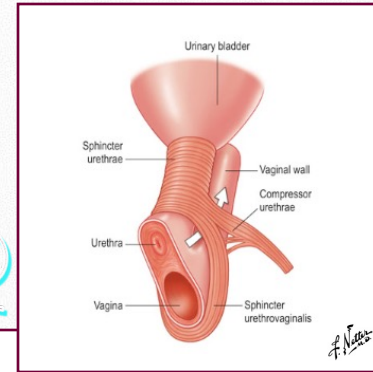


The Clitoris-Urethra-Vagina (CUV) Complex



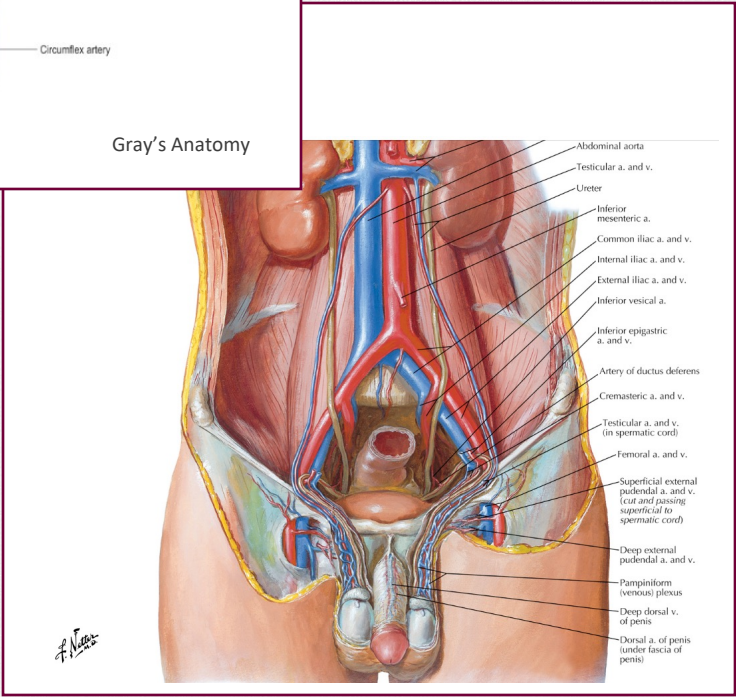
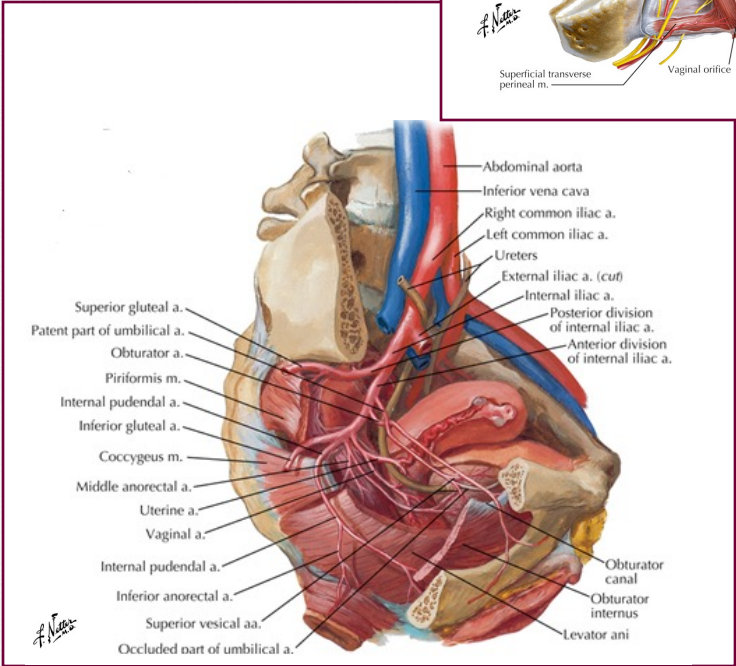
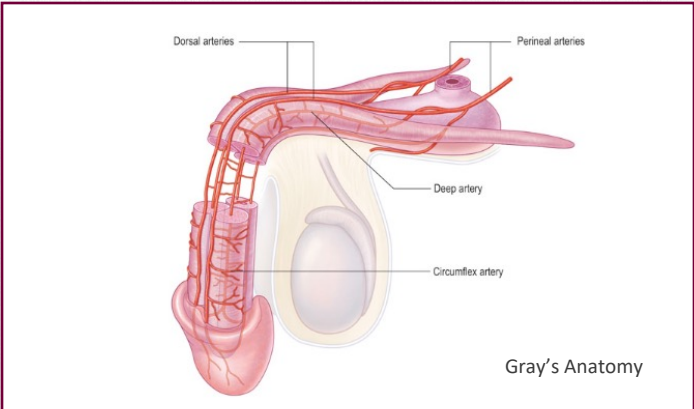
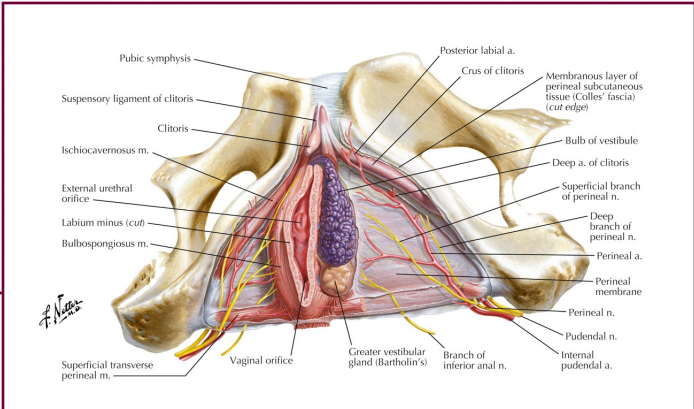
Sexual anatomy and physiology

❖ Pelvic floor muscles



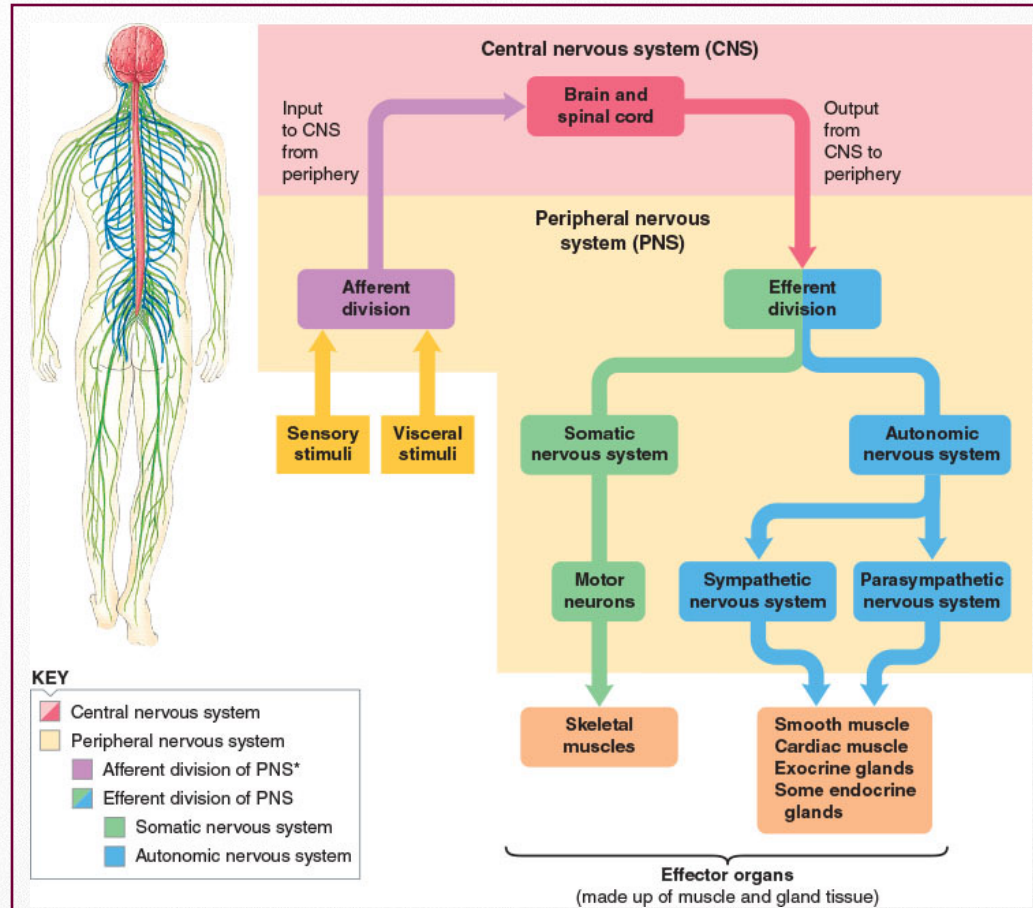
Sexual anatomy and physiology

❖ Genital vascularisation



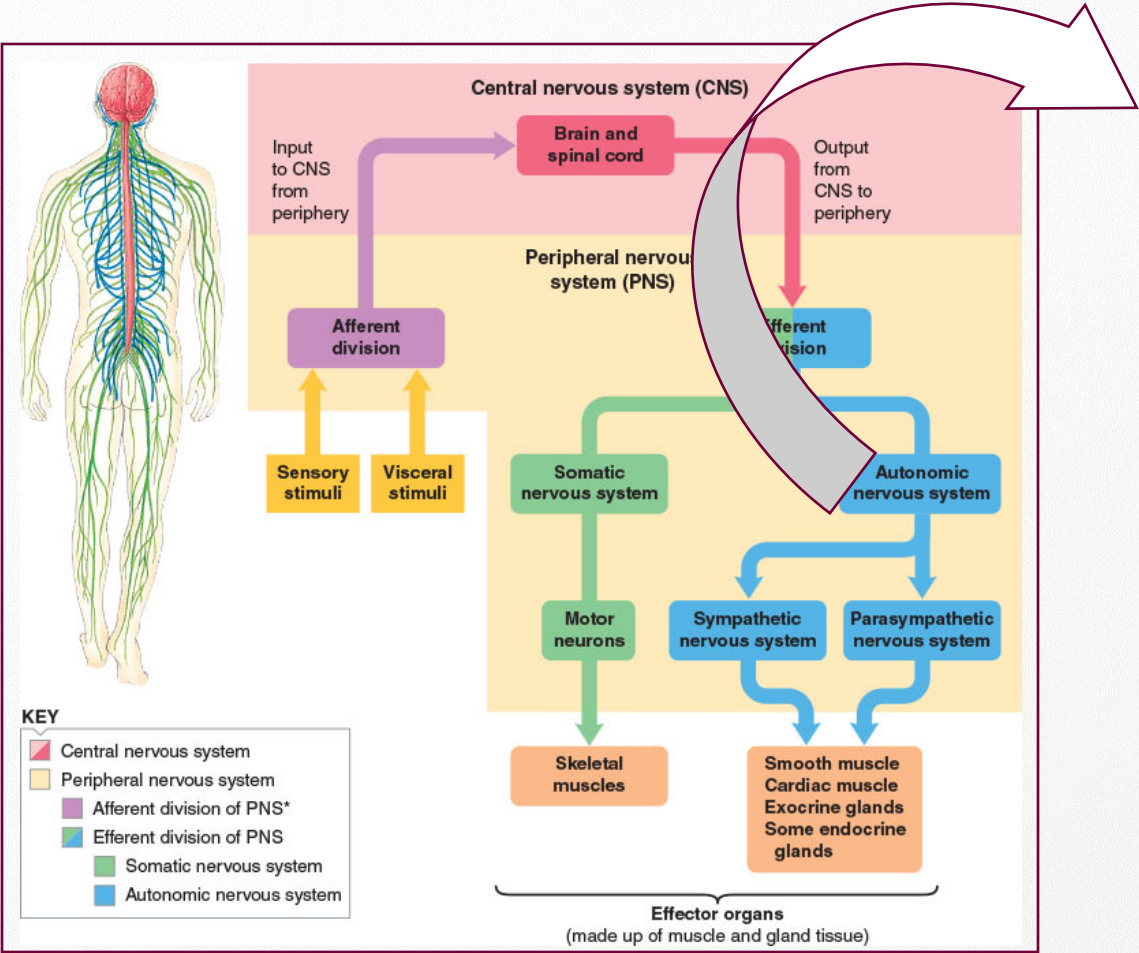
Sexual anatomy and physiology

❖ Central and peripheral nervous system



Sexual anatomy and physiology

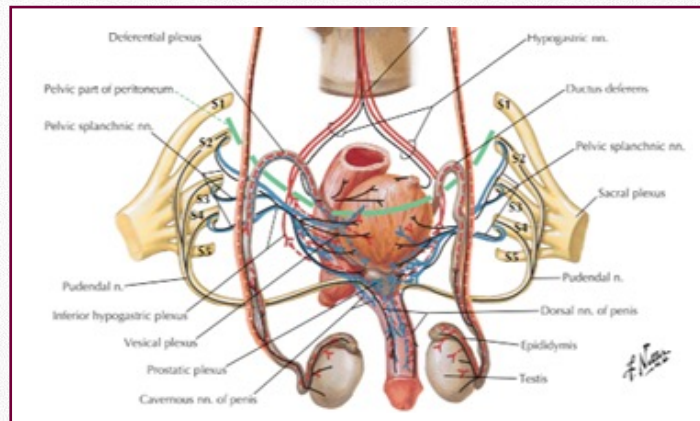
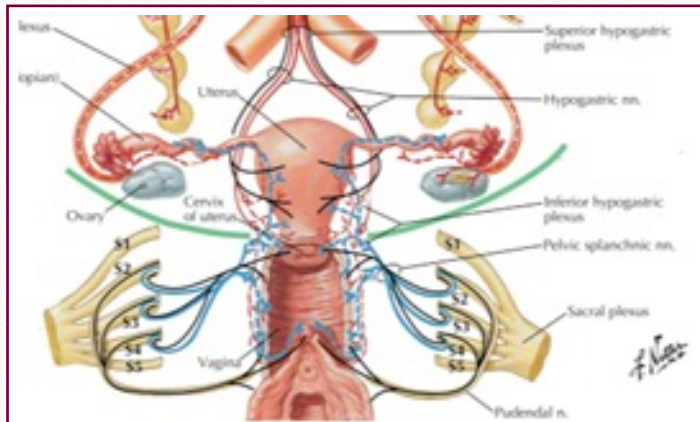
❖ Central and peripheral nervous system



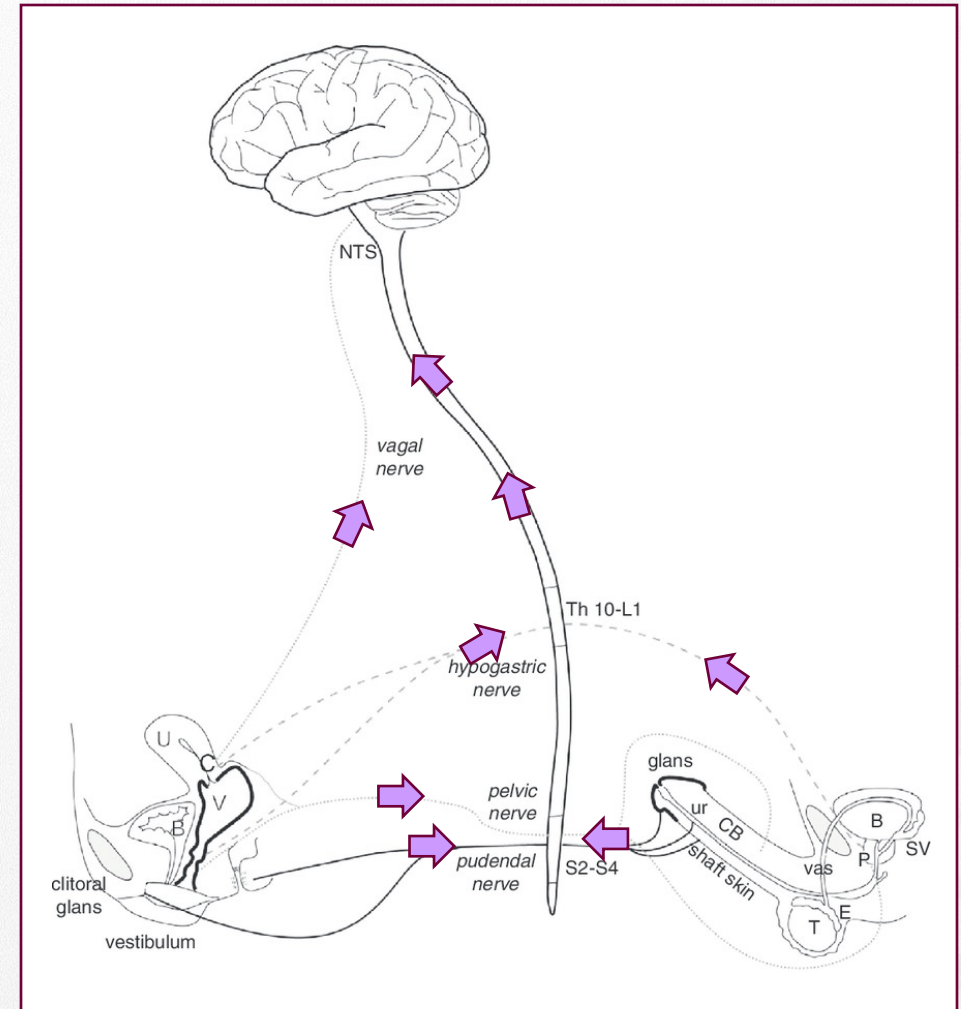
	Sympathetic	Parasympathetic
Localization neurons	Near spinal cord Level Th10-L3	Near genitals Level S2-S4
Neurotransmitter	NA	Acetylcholine Vascular tissue: NA, VIP
Functional	Innervation is strong and global (e.g. ejaculation associated with increased blood pressure, heartrate and respiration)	Innervation is often organ specific (e.g. vasocongestion of clitoral cavernous bodies)

Sexual anatomy and physiology

❖ Central and peripheral nervous system



Sympathetic fibers { Preganglionic ——— Postganglionic - - - - - } Parasympathetic fibers { Preganglionic ——— Postganglionic - - - - - } Afferent fibers ———

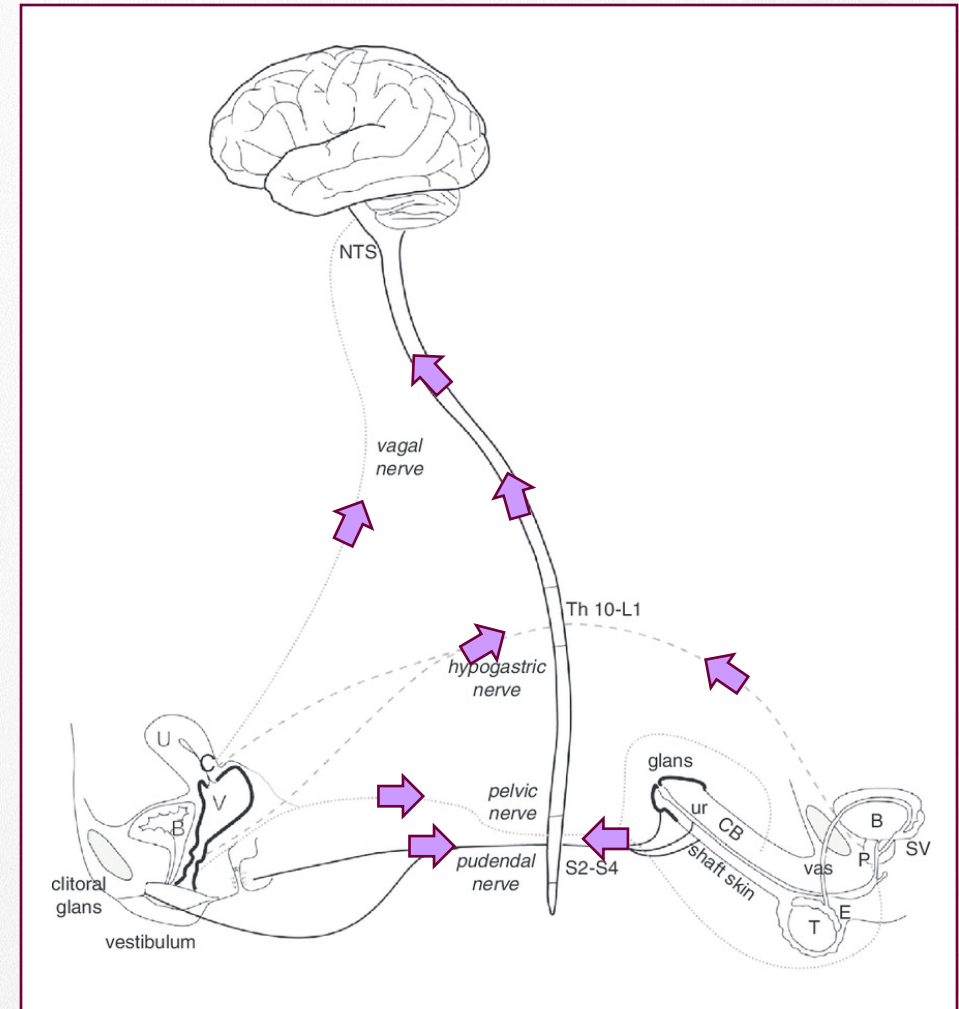
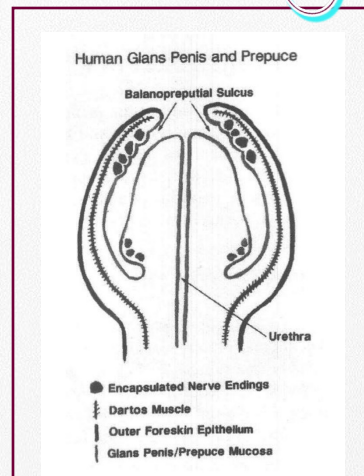
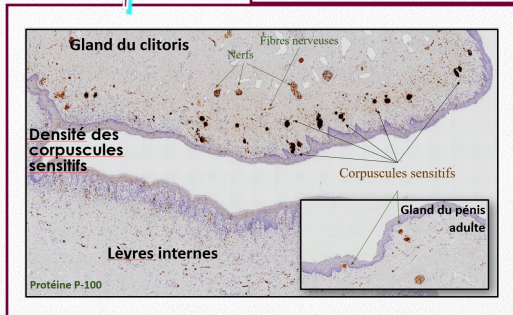
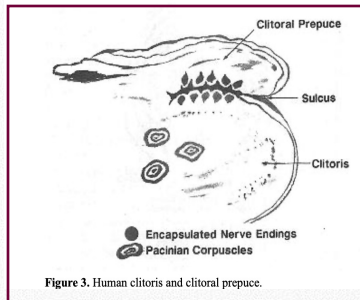


Sexual anatomy and physiology

❖ Central and peripheral nervous system

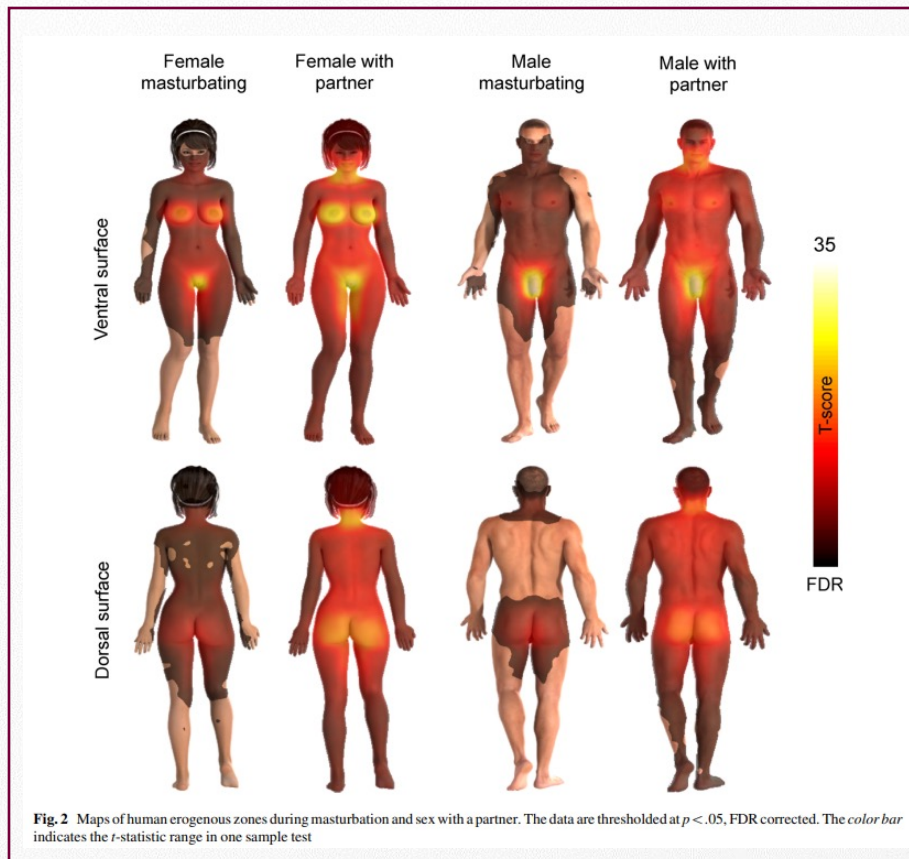
N pudendus:

- Sensibility of the genital skin, clitoris and penis
- Control of pelvic floor muscles and sphincters

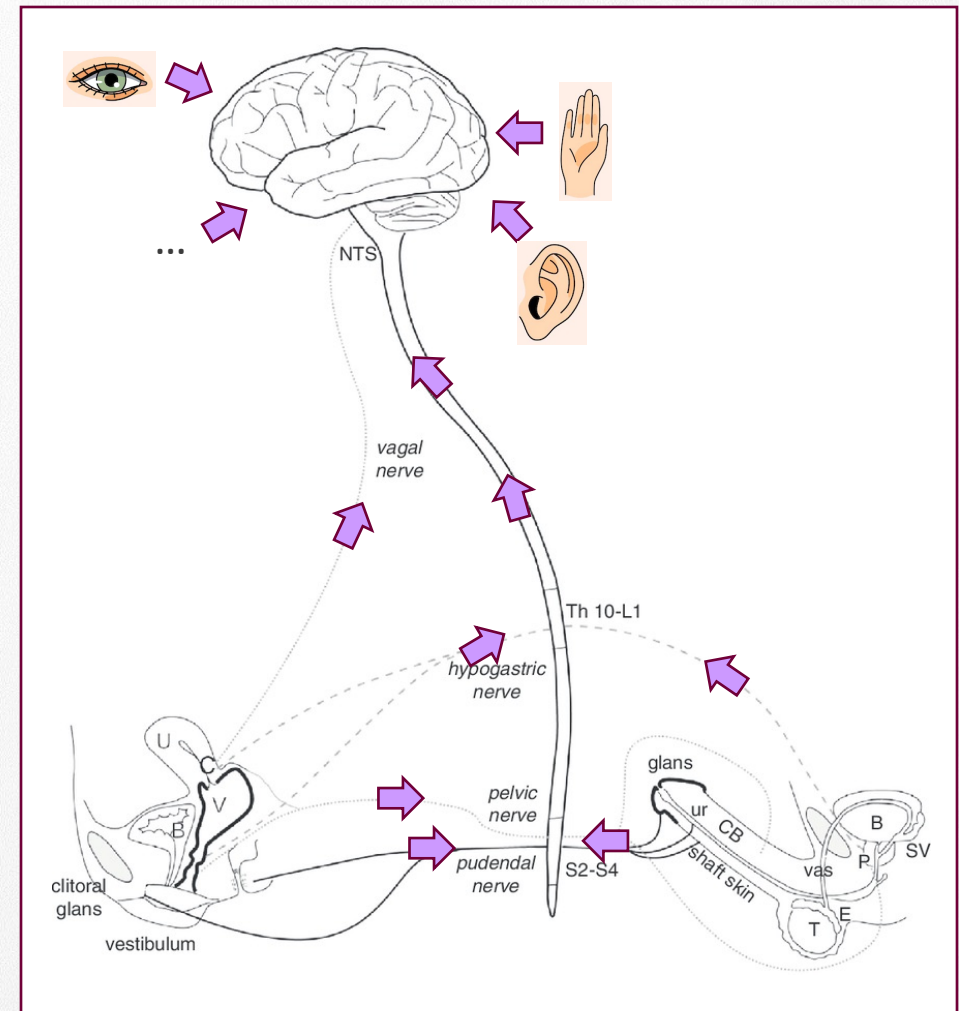


Sexual anatomy and physiology

❖ Central and peripheral nervous system



Nummenma 2016



Anatomical and physiological bases of sexual response

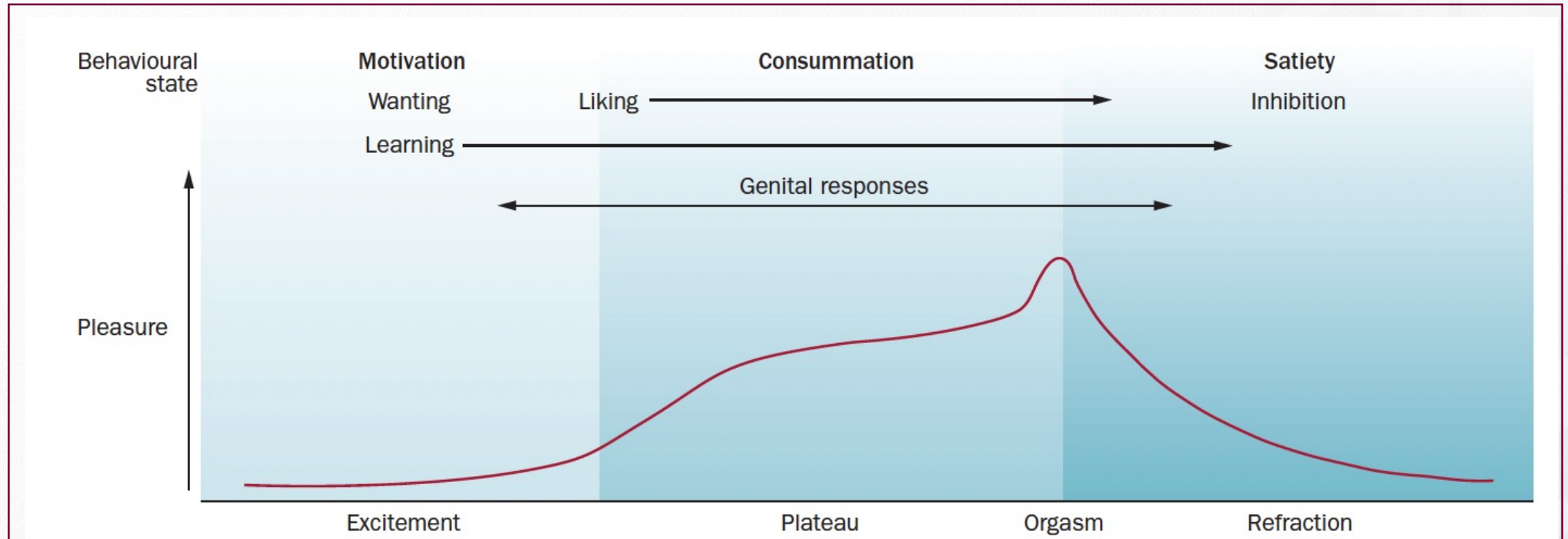
A. Sexual anatomy and physiology

- ❖ Genital anatomy
- ❖ Pelvic floor muscles
- ❖ Genital vascularisation
- ❖ Central and peripheral nervous system

B. Physiological changes during sexual response

C. Steroid hormones and sexuality

Physiological changes during sexual response

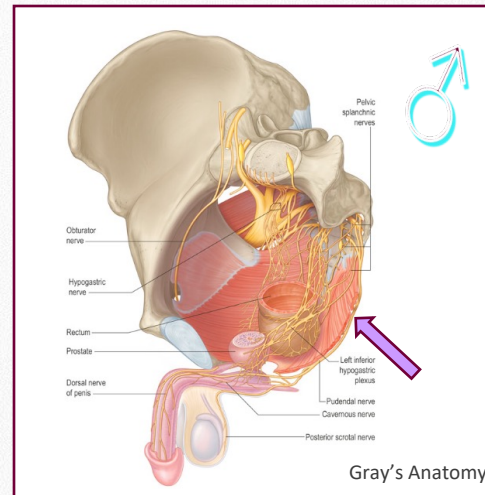
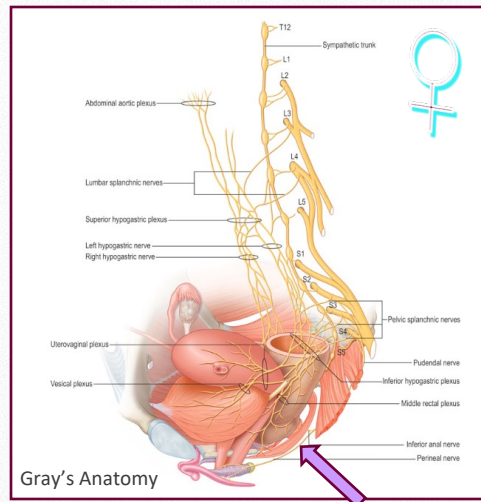


Interplay between pelvic organs, changes in vascularisation, somatic and autonomic (parasympathic and sympathetic) NS.

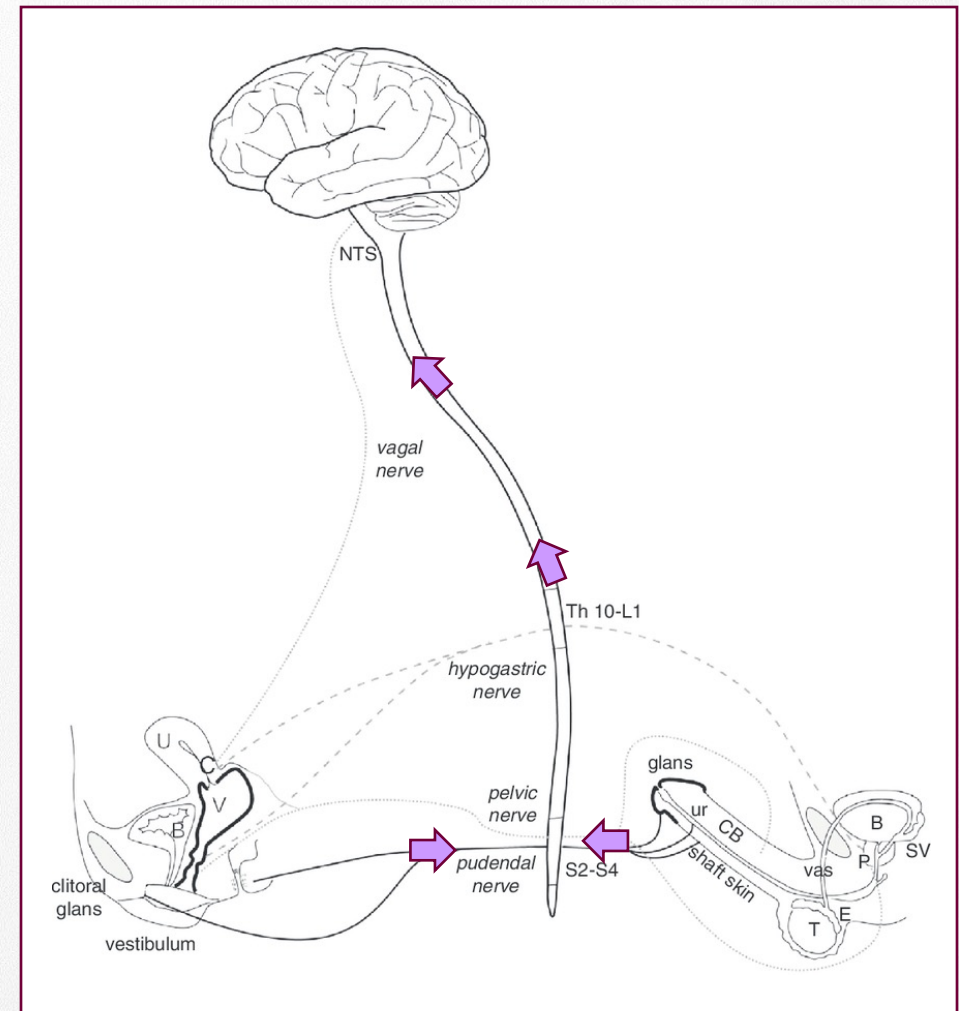
Physiological changes during sexual response

Sexual excitement and arousal

Activation of the nervous system during sexual stimulation
-> for example: vulvar/ penile stimulation

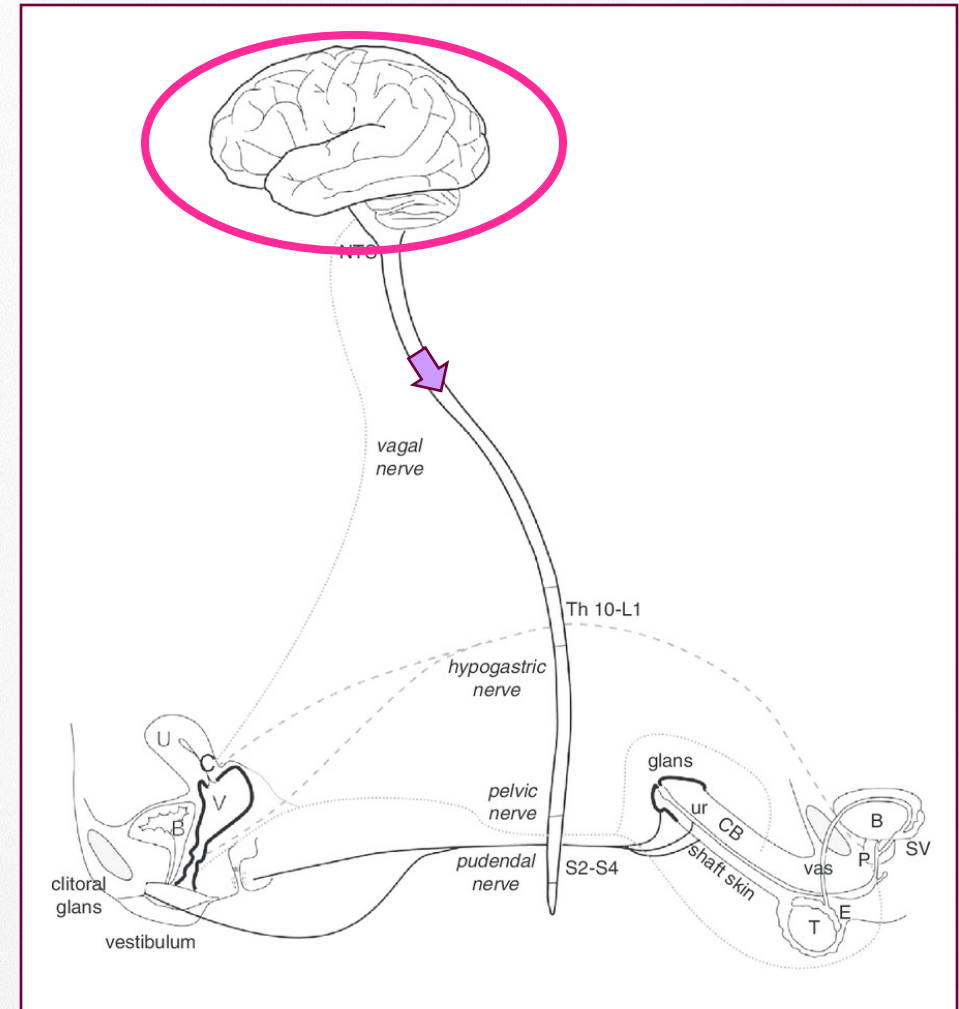
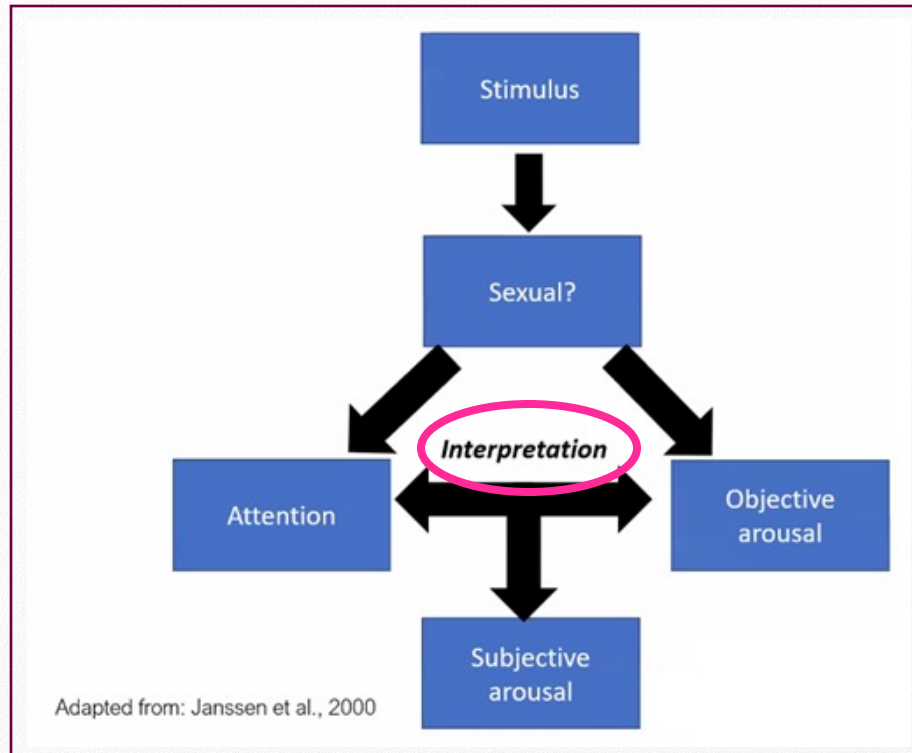


- Receptors of the pudendal nerve
- Somatic afferents
- Spinal cord segments S2-S4



Physiological changes during sexual response

Sexual excitement and arousal



Physiological changes during sexual response

Sexual excitement and arousal

Local increased blood supply and blood pressure
Smooth muscle relaxation => dilation of arteries

Vasocongestion

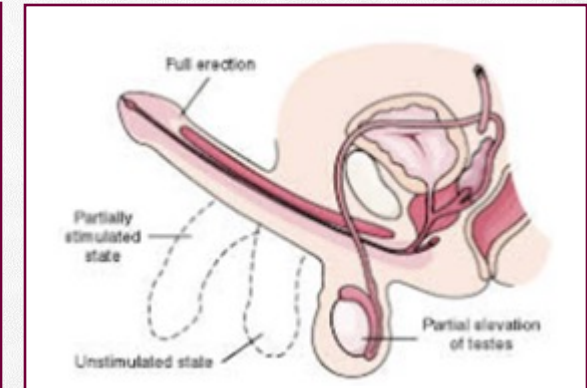
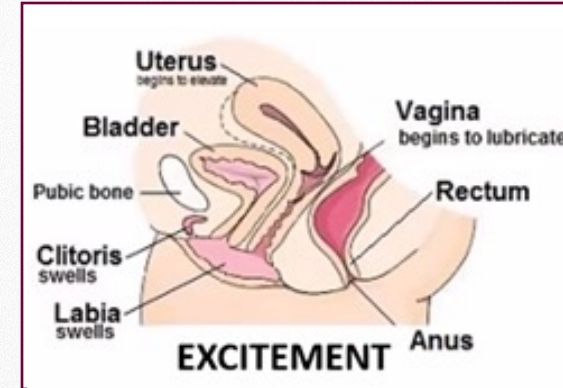
♀: - swelling of vulva (clitoris, labia, vagina, uterus)

- vaginal lubrication (transudation)

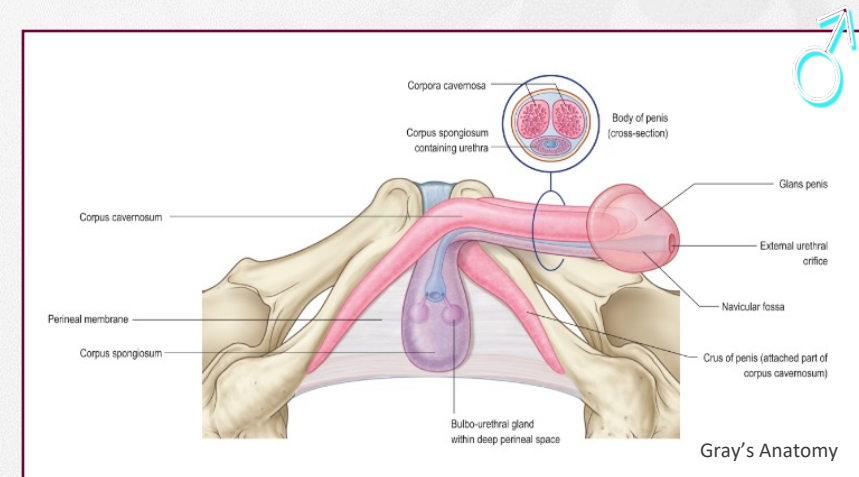
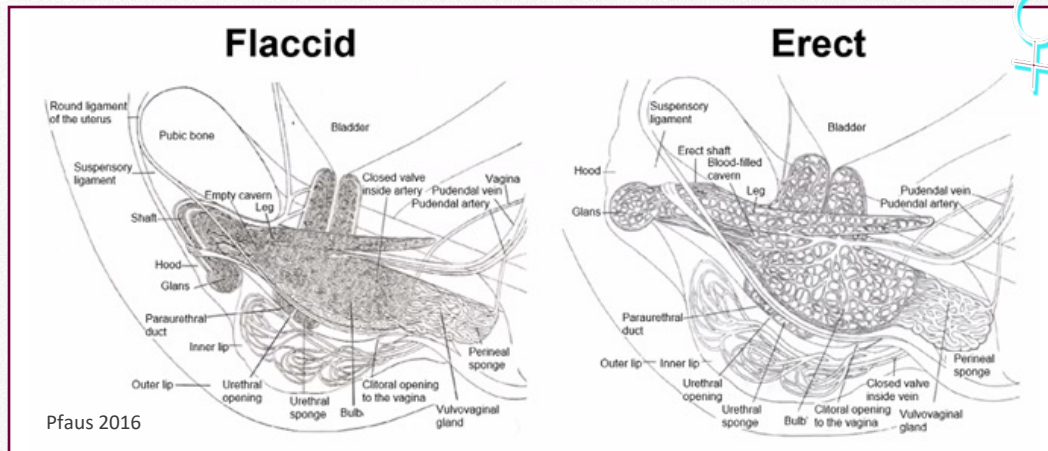
- vestibular gland secretion

♂: - erection

- gland secretion



Salonia A, Giraldo A, Chivers ML, Georgiadis JR, Levin R, Maravilla KR, McCarthy MM. (2010) *J Sex Med.* 7, 2637-2660.



Physiological changes during sexual response

Sexual excitement and arousal

Local increased blood supply and blood pressure
Smooth muscle relaxation => dilation of arteries

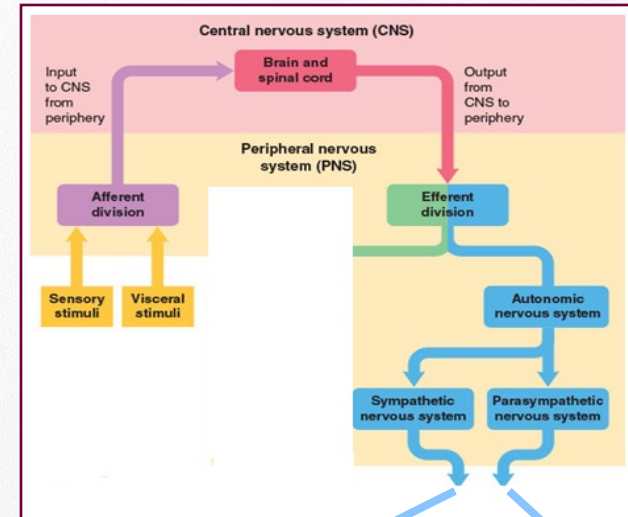
Vasocongestion

♀: - swelling of vulva (clitoris, labia, vagina, uterus)

- vaginal lubrication (transudation)
- vestibular gland secretion

♂: - erection

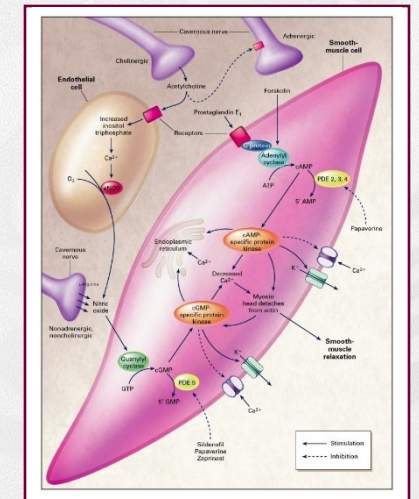
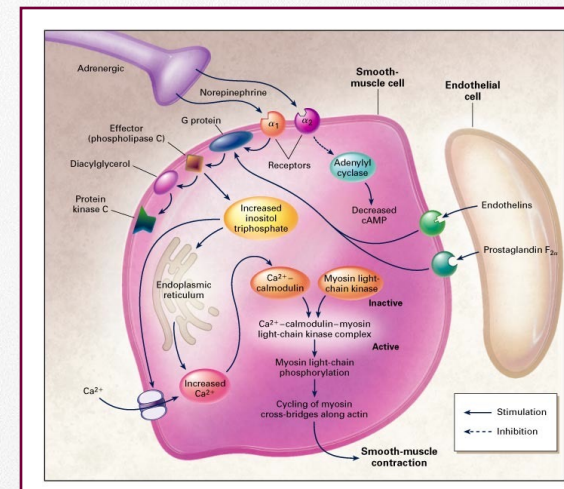
- gland secretion



Inhibition adrenergic transmission

Acetylcholine

NO and VIP



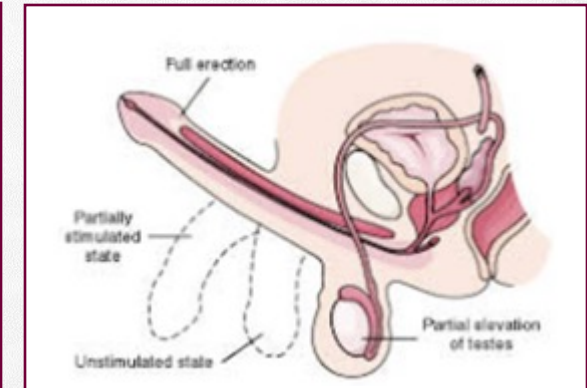
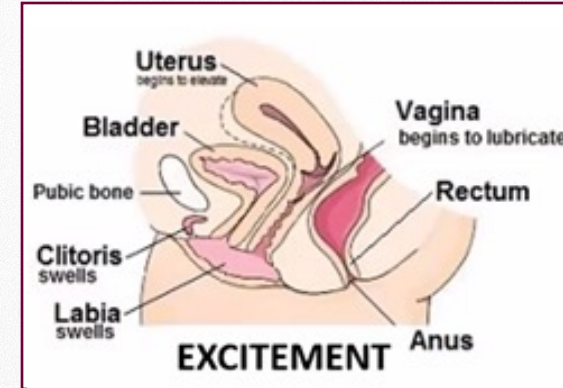
Physiological changes during sexual response

Sexual excitement and arousal

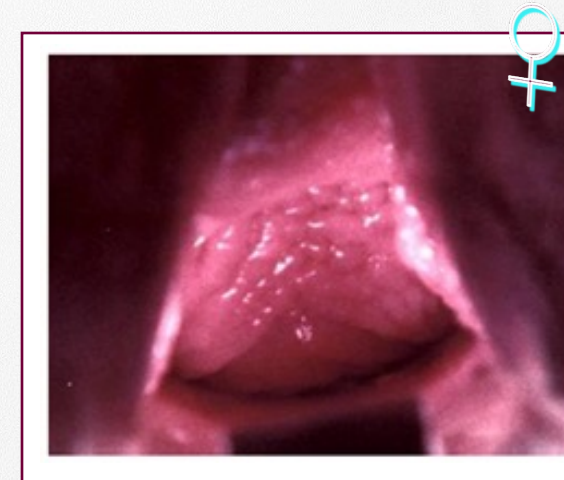
Local increased blood supply and blood pressure
Smooth muscle relaxation => dilation of arteries

Vasocongestion

- ♀: - swelling of vulva (clitoris, labia, vagina, uterus)
- vaginal lubrication (transudation)
- vestibular gland secretion
- ♂: - erection
- gland secretion



Salonia A, Giraldo A, Chivers ML, Georgiadis JR, Levin R, Maravilla KR, McCarthy MM. (2010) *J Sex Med.* 7, 2637-2660.



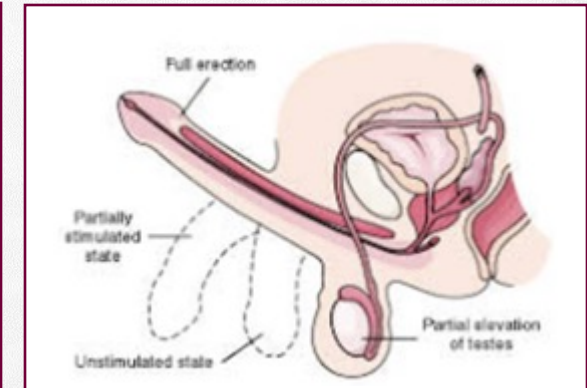
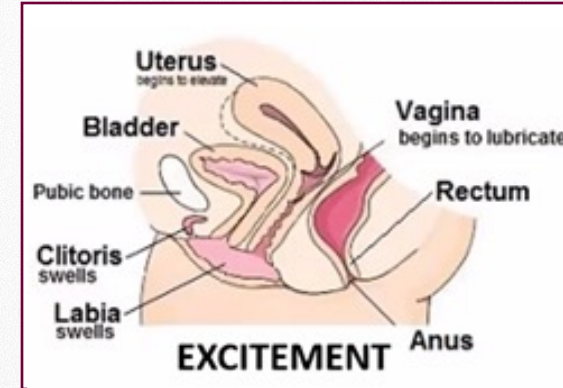
Physiological changes during sexual response

Sexual excitement and arousal

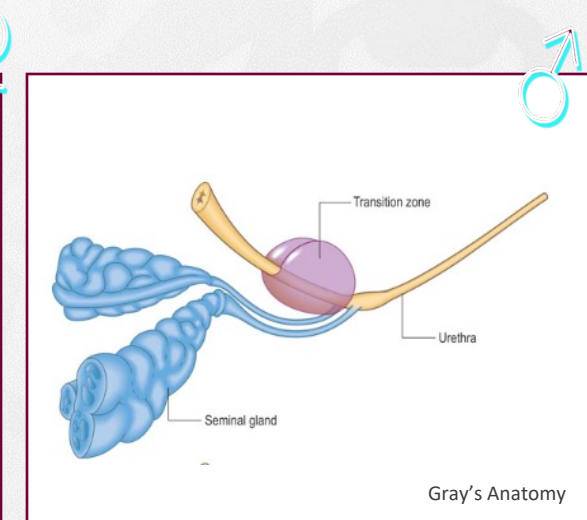
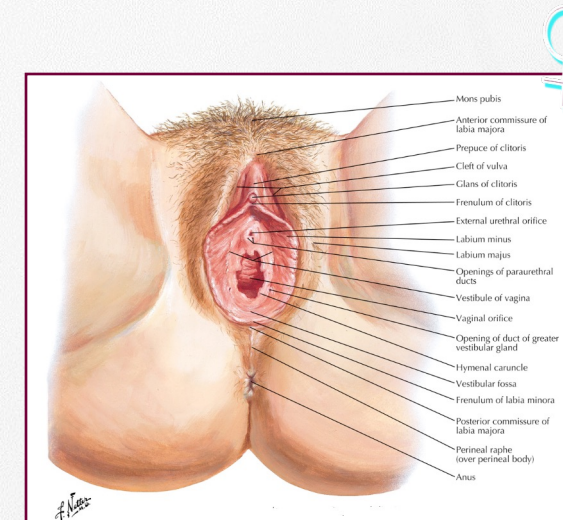
Local increased blood supply and blood pressure
Smooth muscle relaxation => dilation of arteries

Vasocongestion

- ♀: - swelling of vulva (clitoris, labia, vagina, uterus)
 - vaginal lubrication (transudation)
 - vestibular gland secretion
- ♂: - erection
 - gland secretion



Salonia A, Giraldi A, Chivers ML, Georgiadis JR, Levin R, Maravilla KR, McCarthy MM. (2010) *J Sex Med.* 7, 2637-2660.



Gray's Anatomy

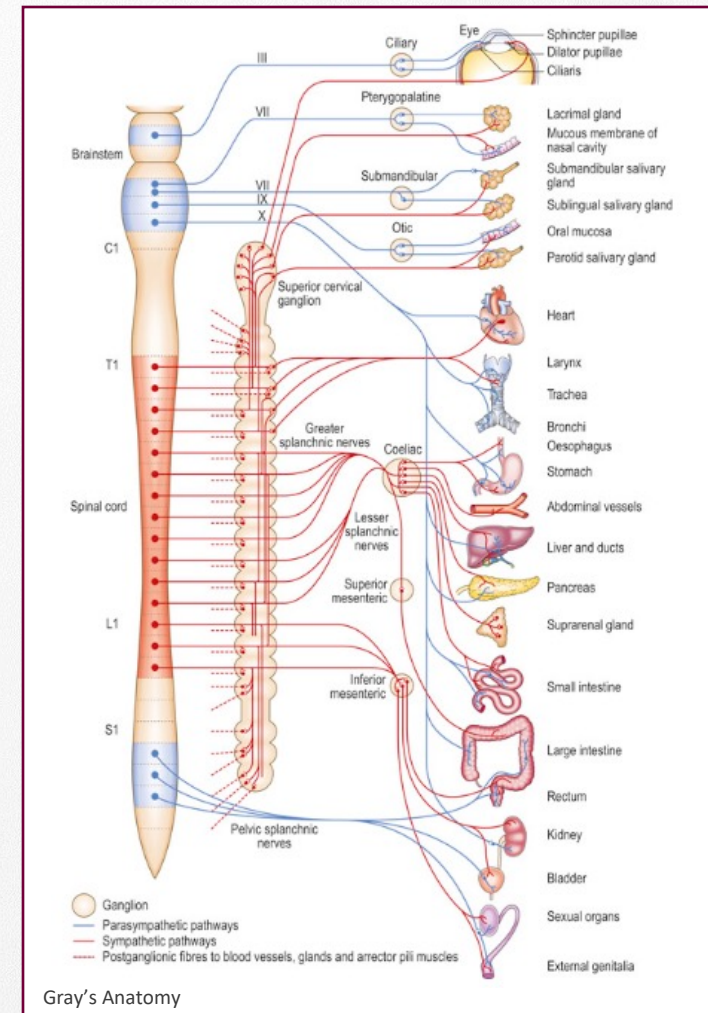
Physiological changes during sexual response

Sexual excitement and arousal

General symptoms

- Increased heart rate, breathing, blood pressure
- Increased pupil dilation
- Better skin conductivity
- Flushing across the chest and upper body

=> increased sympathetic action (NA)



Physiological changes during sexual response

Sexual excitement and arousal

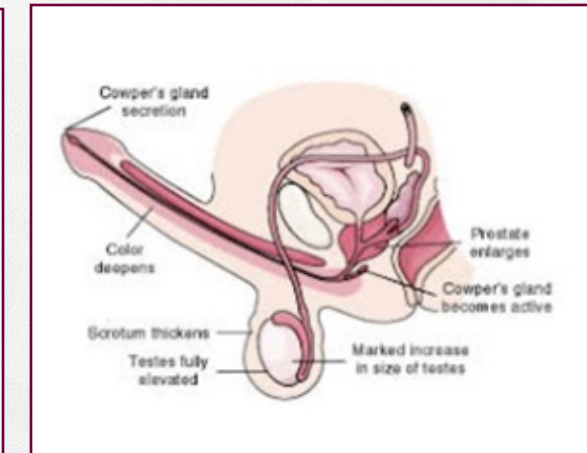
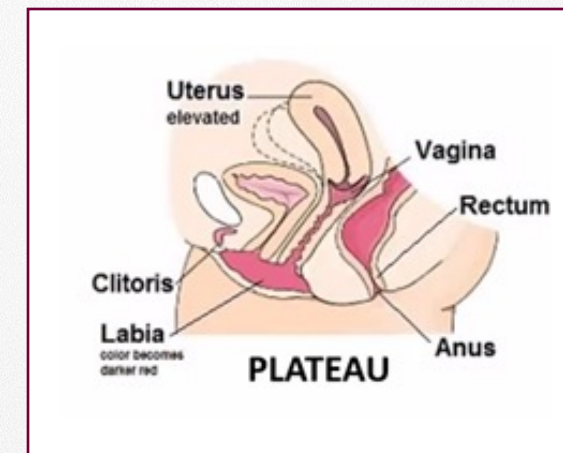
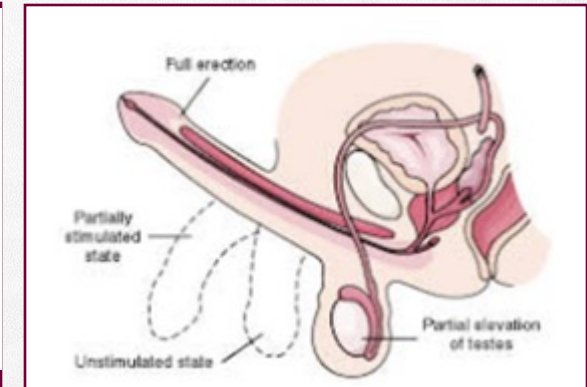
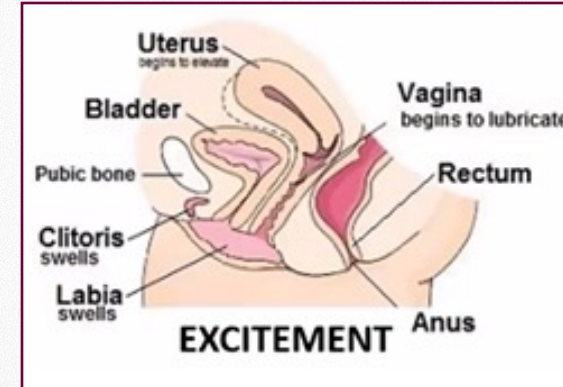
Continuous sexual arousal....



- “tilting” or retroversion of the uterus
- vaginal ballooning or enlargement of fornix posterior
- contraction of pelvic floor muscles: “grasping effect”
- retraction of clitoral gland
- increased fluid secretion of para-urethral and vestibular glands



- elevation of testes and increase size of testes, prostate
- Cowper’s gland secretion



Physiological changes during sexual response

Orgasm

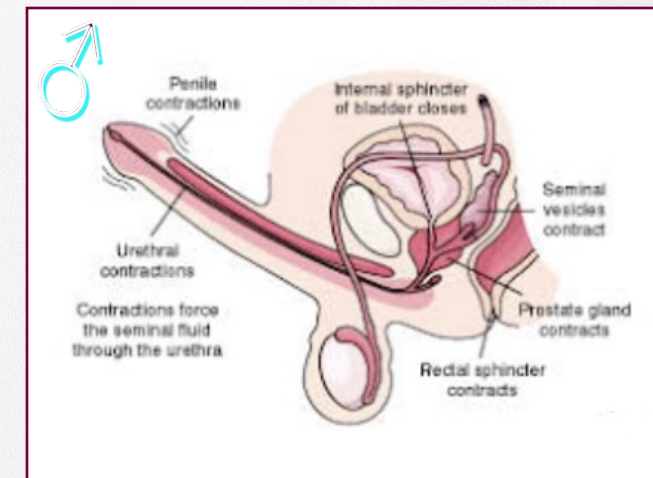
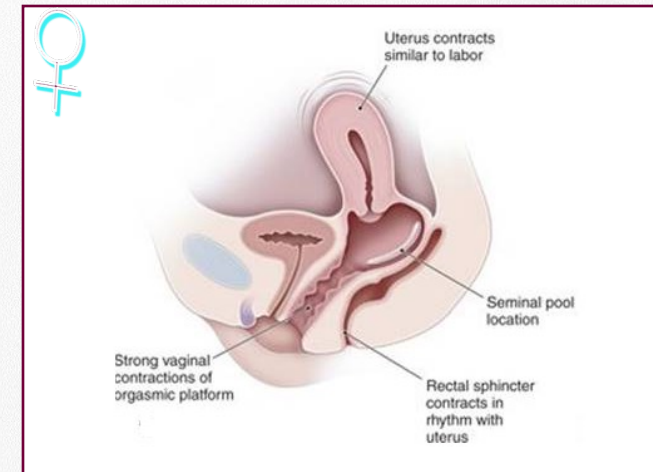
Individual variation in duration, intensity and experience.

Psychological aspects:

- Intense sexual pleasure and excitement
- Altered state of consciousness

Physiological aspects:

- Ejaculation: emission and expulsion
- Uterine contractions
- Involuntary rhythmic pelvic floor muscles contractions
- Increased general physiological changes: heart rate, breathing, blood pressure, pupil dilation, ...



Anatomical and physiological bases of sexual response

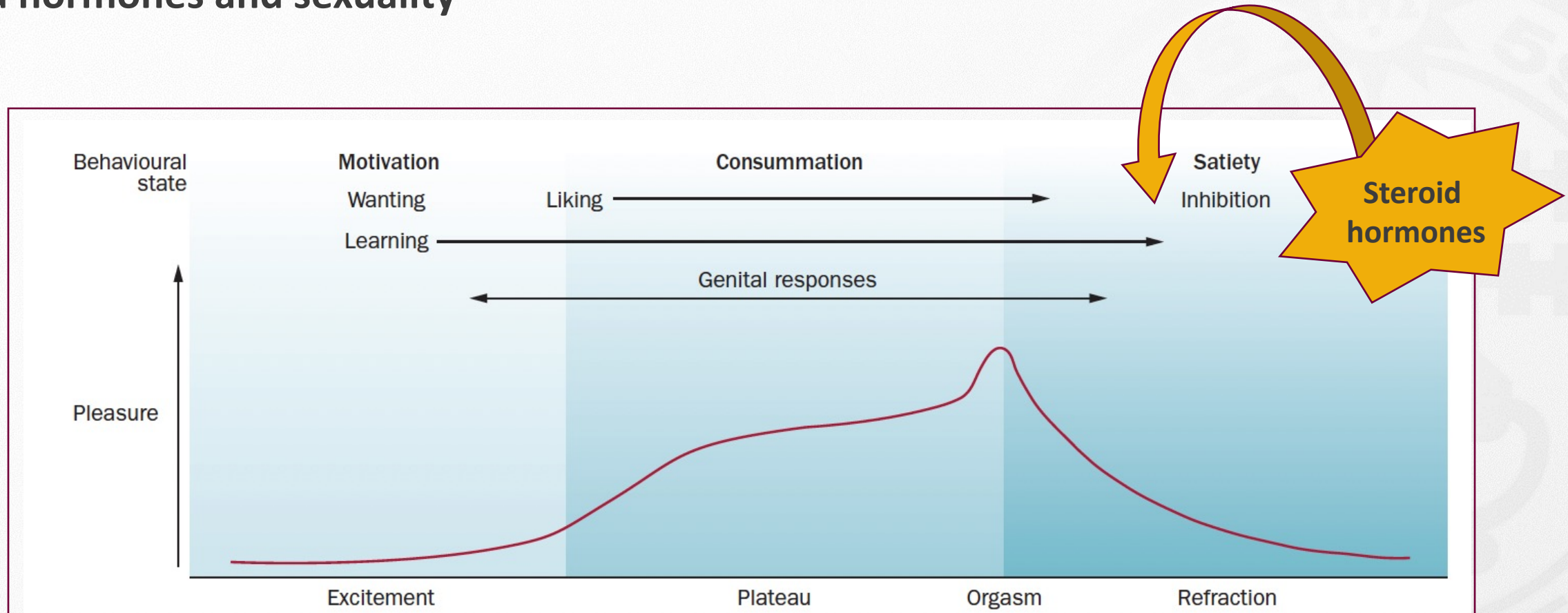
A. Sexual anatomy and physiology

- ❖ Genital anatomy
- ❖ Pelvic floor muscles
- ❖ Genital vascularisation
- ❖ Central and peripheral nervous system

B. Physiological changes during sexual response


C. Steroid hormones and sexuality

Steroid hormones and sexuality



Interplay between pelvic organs, changes in vascularisation, somatic and autonomic (parasympathic and sympathetic) NS.

Steroid hormones = steroid that act like a hormone

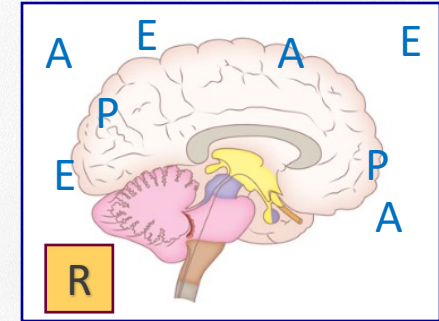


Steroid hormones and sexuality

Central mechanisms



The brain is one of the most important targets for sex hormones



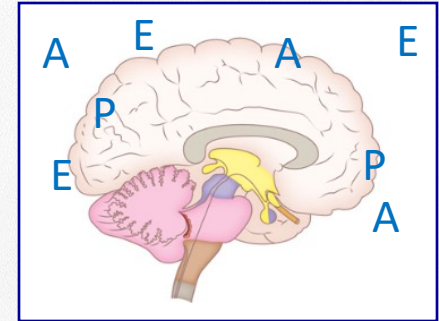
Steroid hormones and sexuality

Central mechanisms



Neuroendocrine mechanisms underlying the influence of sex hormones on sexuality are still not completely understood.

The brain is one of the most important targets for sex hormones



Steroid hormones and sexuality

Central mechanisms

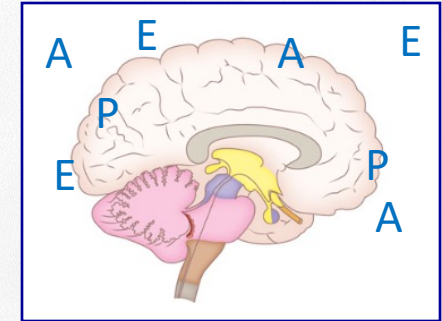


Neuroendocrine mechanisms underlying the influence of sex hormones on sexuality are still not completely understood.

Steroid hormones influence **sexual motivation** and **behavior**.

- ❖ Men reporting a **decreased sexual desire** have **lower concentrations of T**. (Corona 2010)
- ❖ Higher androgenization in men is associated with an **increased frequency of masturbation**. (Corona 2010)
- ❖ Sexual fantasies, sexual desire and the initiation of sexual activity by women peak around the **time of ovulation**.

The brain is one of the most important targets for sex hormones



Steroid hormones and sexuality

Peripheral mechanisms



Androgens influence

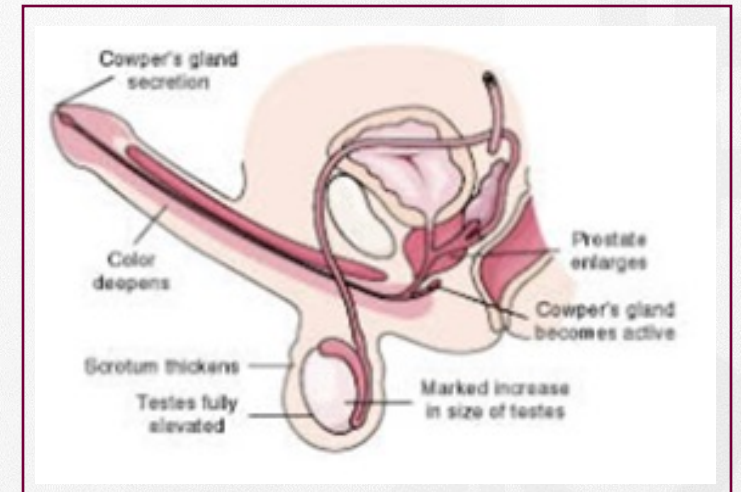
- **Erection**

T influences **smooth muscle contractability**

T regulates **nerve structure and function**

- **Ejaculation**

T plays a facilitatory role in the **control of the ejaculatory reflex**



Steroid hormones and sexuality

Peripheral mechanisms



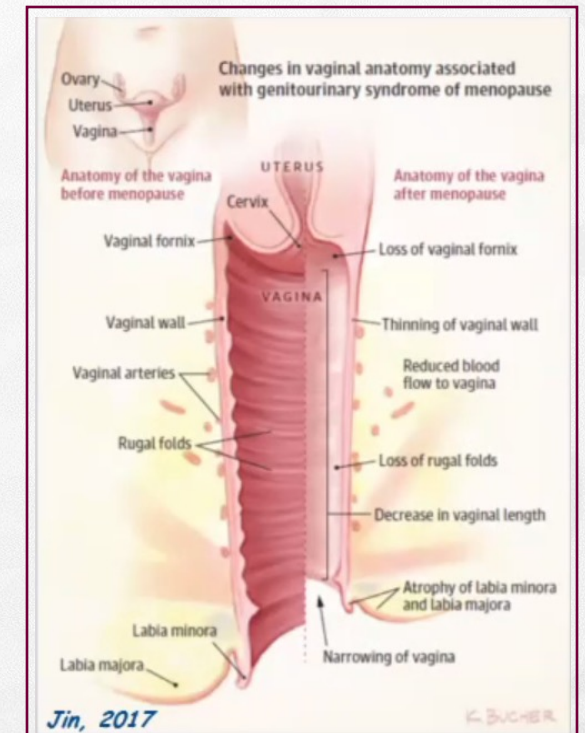
Estrogen and androgens are critical in **preserving vaginal, vulvar health**.

Steroid hormones **influence vaginal and clitoral blood flow, density of collagen fibers in the lamina propria, smooth muscle function, vaginal nerve density and vulvar-vaginal lubrication**.

Absence of adequate levels of sex steroids (menopause, lactation)

=> **VULVO-VAGINAL ATROPHY**

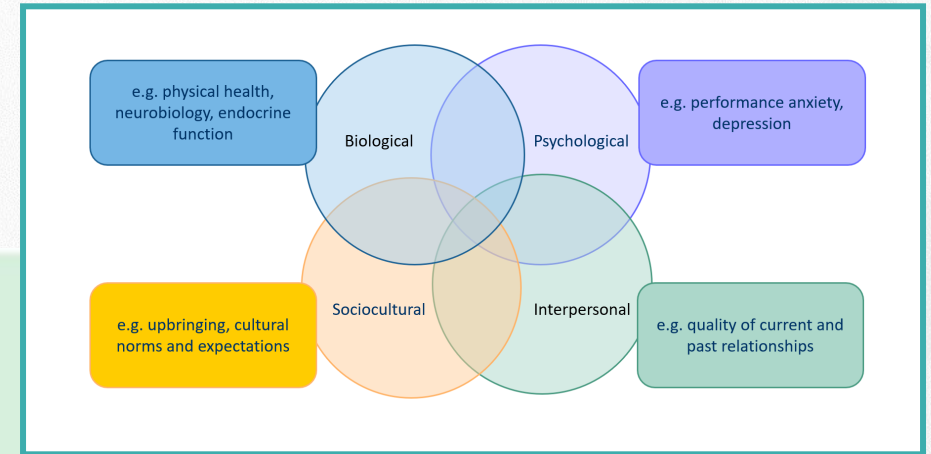
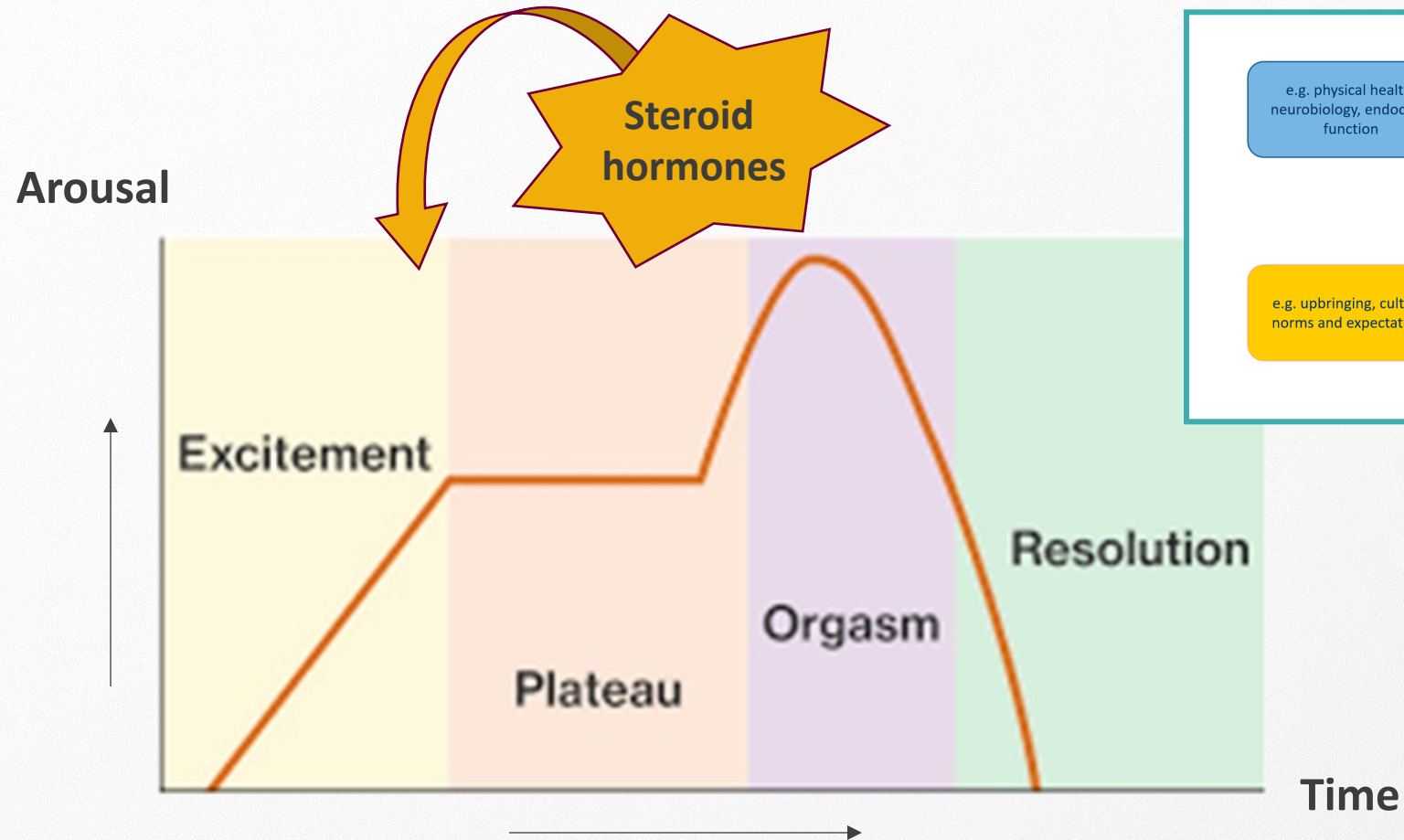
- Friable mucosa that is more sensitive to contact and friction
- Loss of lactobacilli – vaginal pH becomes less acidic – vagina more prone for infection



Conclusion



Conclusion



Interplay between pelvic organs, changes in vascularisation, somatic and autonomic (parasympathic and sympathetic) NS.

Thank you!

